

# Post-COVID-19 Unilateral Upper Lip Numbness: A Case Report

Sofia Maria S. Im, MD and Gerard Saranza, MD

*Section of Neurology, Department of Internal Medicine, Chong Hua Hospital, Cebu City, Cebu, Philippines*

## ABSTRACT

This is a case of a 63-year-old female with post-COVID-19 unilateral upper lip pain and numbness. Neurologic examination did not reveal any deficits other than deficits on pinprick in the maxillary division (V2) of the left trigeminal nerve. Brain neuroimaging showed signs of acute inflammation of the left maxillary sinus. Neuropraxia of the infraorbital nerve, a branch of the trigeminal nerve, was the diagnosis considered. Reports on trigeminal neurosensory changes following acute sinusitis are few, and isolated trigeminal neuropathy is rare except in cases of dental disorders. Up to this writing, there have been no reports on post-COVID-19 unilateral upper lip numbness and pain. This study will also serve as a concise review on the correlative neuroanatomy of the trigeminal nerve.

*Keywords: COVID-19, post-COVID-19 syndrome, unilateral lip numbness, unilateral lip pain, trigeminal nerve*

## INTRODUCTION

The sensory innervation to the face and mucous membranes is provided by the trigeminal nerve through its three branches. Clinical symptoms of nerve damage vary from hypesthesia, to pain, and to paresthesia. Reports on injuries to branches of the trigeminal nerve after oral and maxillofacial treatment have been made; however, up to this writing, there have been no reports of post-COVID-19 unilateral upper lip numbness and pain.<sup>1</sup> The objective of this study is to present a case of a 63-year-old female with post-COVID-19 unilateral upper lip numbness and the correlative neuroanatomy of the trigeminal nerve.

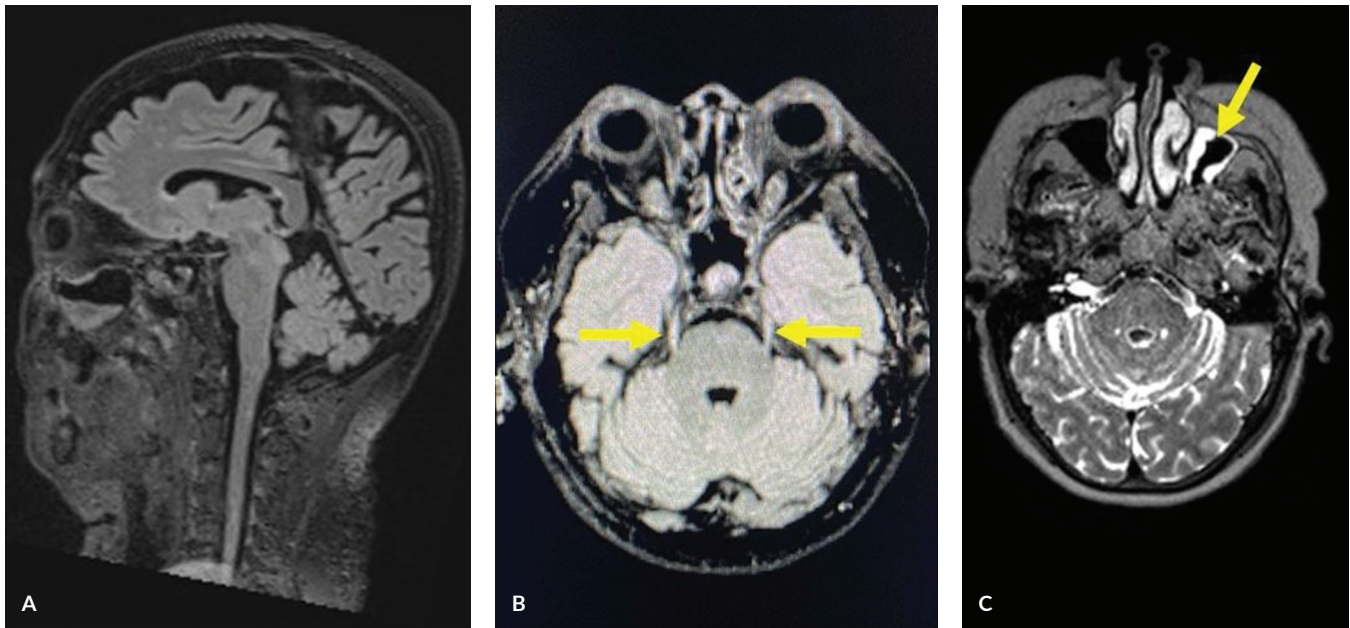
## CASE PRESENTATION

A 63-year-old female was recently admitted for 16 days for moderately severe COVID-19 infection and acute sinusitis due to COVID-19. The patient is a known hypertensive, diabetic, and asthmatic, and has no vices. She was discharged in stable condition, and maintained on prophylactic anti-coagulation due to increased inflammatory markers. Two weeks later, she was re-admitted due to complaints of malaise and sharp, shooting pain, and numbness of the left upper lip. This was preceded by nasal congestion, pain in the left side of her face, and one episode of epistaxis. She denied having diplopia, facial asymmetry, dizziness, and dysarthria. Neurologic examination did not reveal any deficits other than deficits on pinprick in the maxillary division (V2) of the left trigeminal nerve. She had good masseter and temporalis tone; corneal reflex was intact. Complete blood



eISSN 2094-9278 (Online)  
Published: March 15, 2024  
<https://doi.org/10.47895/amp.vi0.6796>

Corresponding author: Sofia Maria S. Im, MD  
Section of Neurology  
Department of Internal Medicine  
Chong Hua Hospital  
Don Mariano Cui St., Brgy. Capitol Site,  
Cebu City, Cebu, 6000 Philippines  
Email: [sofiaimmd@gmail.com](mailto:sofiaimmd@gmail.com)  
ORCID: <https://orcid.org/0000-0002-6817-6040>



**Figure 1.** (A) Sagittal T2 Flair image of the brain. (B) Axial T2 Flair image at the level of the pons showing a normal cisternal segment of the trigeminal nerve (yellow arrows), and the absence of any acute infarcts or other lesions. (C) Axial T2 image of the brain at the level of the mid-pons showing left maxillary sinusitis (yellow arrow).

count showed a decreased white blood cell count ( $4.52 \times 10^3/\mu\text{L}$ ), with a normal neutrophil and lymphocyte count. On neuroimaging, there were no acute infarcts or intracranial lesions, but signs of acute inflammation of the left maxillary sinus were noted (Figure 1). Neuropraxia of the infraorbital nerve secondary to acute left maxillary sinusitis was considered. She was then treated with antibiotics, B12 supplementation, and pregabalin.

Our case presented with an isolated unilateral upper lip numbness on the background of left maxillary sinusitis. The differential diagnosis include infective and inflammatory etiologies of isolated maxillary sinusitis including COVID-19, chronic sinusitis, odontogenic maxillary sinusitis, osteomyelitis, and chronic maxillary atelectasis. Our consideration for differential diagnosis also encompassed non-sinusitis-related causes including a lesion in the left maxillary nerve from its origin towards the brainstem.<sup>1</sup> The patient was managed as a case of neuropraxia secondary to sinusitis. She was started on Vitamin B complex, one capsule once a day for three months, and Pregabalin, 50 mg capsule, as needed for pain. For patients with neuropraxic injuries, conservative treatment is recommended. Vitamin B Complex helps to alleviate degeneration in the nervous system and enhance peripheral nerve regeneration.<sup>2</sup> Pregabalin is a neuropathic pain medication and was given to relieve the shooting pain the patient was experiencing. Neuropraxia has an excellent prognosis since it is a non-axonal injury. Most patients recover within two to three months.<sup>3</sup> Our patient improved after three months with no neurologic deficit.

## DISCUSSION

The trigeminal nerve has three peripheral branches: ophthalmic (V1), maxillary (V2), and mandibular (V3). The peripheral branches of V2 include the middle meningeal nerve, zygomatic nerve, pterygopalatine nerve, branches for the nasal cavity, palatine nerve, posterior superior alveolar nerve, infraorbital nerve. The maxillary branch supplies the upper lip, lateral and posterior portions of the nose, upper cheek, anterior temple, mucosa of the nose, maxillary sinus, upper jaw, upper teeth, roof of the mouth, and dura of the middle cranial fossa.<sup>4</sup> It is the maxillary branch of the trigeminal nerve, specifically the infraorbital nerve that was affected in our patient.

Reports on trigeminal neurosensory changes following acute sinusitis and COVID-19 are few, and isolated trigeminal neuropathy is rare except in cases of dental disorders (Table 1). A 47-year-old man with sinusitis presented with isolated trigeminal sensory neuropathy mainly involving the first branch with ocular proptosis and eyelid edema. His brain imaging revealed no abnormality, however, clinical findings in this case suggested invasion of the paranasal infection into the orbit and cavernous sinus.<sup>5</sup> In another case, a 67-year-old man with a preceding upper respiratory tract infection presented with tactile sense and thermal nociception impairment in areas corresponding to the second branch of the trigeminal nerve. Head computed tomography showed fluid accumulation without bone destruction in the right sphenoidal sinus. From this study, it was assumed that inflammation in the sphenoidal sinus had spread to the

**Table 1.** Reports on Isolated Trigeminal Neurosensory Changes following Sinusitis

Author, Publication Year	Age, Gender	Neurologic Manifestation	Brain Imaging Findings	Specific Branch of CN V Affected	Purported Etiology
Okuda, 1994	47/M	Ocular proptosis Eyelid edema	No abnormality	V1: Ophthalmic Branch	Sinusitis
Yuta, 2016	67/M	Tactile sense and thermal nociception impairment in areas corresponding to the second branch of the trigeminal nerve	Fluid accumulation without bone destruction in the right sphenoidal sinus	V2: Maxillary Branch	Upper respiratory tract infection
Molina-Gil, 2021	65/M	Paroxysmal lancinating pain in the right trigeminal V1 territory	Not performed	V1: Ophthalmic Branch	COVID-19

foramen rotundum and the second branch of the trigeminal nerve passing through the foramen.<sup>6</sup> Trigeminal neuralgia as the sole manifestation of COVID-19 was reported in an article by Molina-Gil, et al. A 65-year-old man presented with typical respiratory symptoms of COVID-19 and paroxysmal lancinating pain in the right V1 trigeminal territory without other neurologic symptoms. Neuroimaging was not done.<sup>7</sup> Up to this writing, there have been no reports on unilateral upper lip numbness post-COVID-19 sinusitis infection.

Studies on the neuroinvasive potential of Coronavirus have discovered that SARS-CoV-2 affects the nervous system through direct infection or via its systemic effects on the whole body. Peripheral nerves may spread SARS-CoV-2 into the brain through the retro-neural route. A possible pathway is afferent parts of the olfactory nerve, trigeminal nerve, glossopharyngeal nerve, vagus nerve, dorsal root ganglion, allow the virus to spread from the surrounding to the central nervous system. In addition, the human ACE2 protein, a virus binding site, may be expressed at low levels in neurons. Also, when SARS-CoV-2 invades cells, it can induce damage-related molecular patterns leading to the production of cytokines. At the same time, SARS-CoV-2 causes the activation of inflammasome complexes and the release of interferon and interleukin. If the inflammatory process is out of control, a cytokine storm and a systemic inflammatory syndrome will occur throughout the body.<sup>8</sup>

**CONCLUSION**

Up to this writing, there have been no reports of neuropraxia of the second branch of the trigeminal nerve post-COVID-19 infection. Neuropraxia has an excellent prognosis with most patients recovering within two to three months.

**Ethical Considerations**

The authors certify that they have obtained appropriate patient consent forms granting use of the patient’s images and clinical information for publication. The patient understands that her name and initials will not be published and due efforts will be made to conceal her identity but anonymity cannot be guaranteed.

**Statement of Authorship**

SMSI contributed in writing both the revised and final manuscript. GRMS contributed in the conceptualization of work and final approval of version to be published.

**Author Disclosure**

Both authors declared no conflicts of interest.

**Funding Source**

No specific grant from any funding agency in the public, commercial or not-for-profit sectors was received in writing this paper.

**REFERENCES**

- Lau HT, Lim KH. Isolated unilateral upper alveolar numbness in silent sinus syndrome. *BMJ Case Rep.* 2017 Mar; 2017:bcr2017219322. doi: 10.1136/bcr-2017-219322.
- Altun I, Kurutas EB. Vitamin B complex and Vitamin B12 levels after peripheral nerve injury. *Neural Regen Res.* 2016 May;11(5):842-5. doi: 10.4103/1673-5374.177150.
- Menorca RMG, Fussell TS, Eifar JC. Nerve p hysiology: mechanisms of injury and recovery. *Hand Clin.* 2013 Aug;29(3):317-30. doi: 10.1016/j.hcl.2013.04.002.
- Kamel HA, Toland J. Trigeminal nerve anatomy: illustrated using examples of abnormalities. *AJR Am J Roentgenol.* 2001 Jan;176(1): 247-51. doi: 10.2214/ajr.176.1.1760247.
- Okuda B, Tachibana H, Sugita M. Trigeminal sensory neuropathy with abnormal taste following acute sinusitis. *Clin Neurol Neurosurg.* 1994 Feb;96(1):83-5. doi: 10.1016/0303-8467(94)90035-3.
- Hirose Y, Hirota Y, Yokokawa D, Ohira Y, Ikusaka M. Acute sphenoiditis involving the second branch of the trigeminal nerve. *QJM.* 2016 Nov;109(11):745-6. doi: 10.1093/qjmed/hcw156.
- Molina-Gil J, Gonzalez-Fernandez L, Garcia-Cabo C. Trigeminal neuralgia as the sole neurological manifestation of COVID-19: A case report. *Headache.* 2021 Mar; 61(3):560-2. doi: 10.1111/head.14075.
- Xie Z, Hui H, Zhao Z, Yu W, Wu R, Zhu Y, et al. Nervous system manifestations related to COVID-19 and their possible mechanisms. *Brain Res Bull.* 2022 Sep;187:63-74. doi: 10.1016/j.brainresbull.2022.06.014.