

A Case of a 38-year old Female with Right-sided Weakness, Hypertension and Hypokalemia

Maria Luisa Cecilia C. Rivera-Arkoncel,¹ Amado O. Tandoc III² and Agnes D. Mejia¹

¹Department of Medicine, College of Medicine and Philippine General Hospital, University of the Philippines Manila

²Department of Pathology, College of Medicine, University of the Philippines Manila

PRESENTATION OF THE CASE

This patient is a 38 year old housewife who has been hypertensive and hypokalemic since age 23. She suffered her first stroke at age 32 and a seizure just one week prior to admission. This paper will discuss the clues to the diagnosis of secondary hypertension.

Case

At age 23 (15 years PTA), our patient complained of generalized body weakness, occasional headache, diaphoresis, heat intolerance, and weight loss despite good appetite. She was diagnosed to be hypertensive (BP of 180/100) and hypokalemic, the latter condition manifesting as recurrent episodes of weakness of both lower extremities, occurring 1–2x/month. Potassium (K⁺) supplements relieved her symptoms. Anti-hypertensive medications were prescribed, but taken with poor compliance. Instead, she took the K⁺ supplement whenever symptoms of leg weakness recurred.

At age 32 (6 years PTA), the patient had cardiomegaly by CXR. At age 37, she suffered her first cerebrovascular disease (CVD): Cerebral infarct, right temporoparietal area. She had left hemiparesis and slurred speech. Over the ensuing months, there was improvement in her motor strength and speech.

One week PTA, she complained of dizziness and weakness of both lower extremities. The day before admission, she had another CVD with sudden onset of expressive aphasia and right-sided hemiparesis.

The patient denies any family history of hypertension, heart disease, diabetes mellitus and cerebrovascular disease. She had four pregnancies, the first at age 17, and the last at age 23, around 5 months prior to the onset of illness. The first three pregnancies were delivered via normal spontaneous delivery, while the last one was via Caesarean

section, the indication for which was unknown. All pregnancies reached term. There was no recalled history of pre-eclampsia/eclampsia. The second child died of pneumonia at 9 months of age.

At the emergency room, pertinent physical findings were: vital signs BP:150/110; in atrial fibrillation with controlled heart rate of 90 bpm; respiratory rate of 20 cpm. The thyroid gland was not enlarged, the apex beat was at the 6th ICS along the anterior axillary line. There was no bruit appreciated in the carotid, abdominal and femoral areas. On neurological exam, the patient was awake with no verbal output but able to follow commands. Cranial CT scan on admission showed a chronic infarct on the right temporoparietal region and a subacute infarct on the left temporal region (Figures 1A and 1B).

The patient stayed in the Neurology ward for 11 days for her cerebral infarct. She was treated with coumadin, aspirin, simvastatin and captopril. Hypokalemia (2.0–2.7 mmol/L) and hypernatremia (155–175 mmol/L) were persistent in spite of correction (Figure 2). There was a gradual improvement in motor strength. Since the neurologic status was stable, the service deemed it best to transfer her to Medicine for further workup.

The patient stayed in the Medical Ward for 12 days. She developed nosocomial pneumonia, initially treated with Cefepime while awaiting the results of the septic work-up. The service also referred her to the Renal Service for the etiology of her hypertension. The latter considered hyperaldosteronism (based on hypernatremia, hypokalemia and hypertension in the young). Renal artery stenosis was also considered (based on a smaller left kidney compared with the right) and renal tubular acidosis I, incomplete (based on persistent hypokalemia and medullary nephrocalcinosis on KUB-UTZ) (Tables 1–4).

She continued to deteriorate from the 16th hospital day onwards with acute kidney injury (creatinine increased from 189–671 mmol/L) (Table 2) and uremic encephalopathy requiring hemodialysis. She had seizures but with no new cerebral infarct and had progression of the pneumonic infiltrates as well as catheter-related UTI (*Alcaligenes faecalis* sensitive to Cefepime). Sepsis with jaundice complicated her clinical course.

Corresponding author: Agnes D. Mejia, MD
Department of Medicine
Philippine General Hospital
Taft Avenue, Ermita, Manila 1000 Philippines
Telephone: +632 5548400 local 2200/2206
Telefax: +632 5264372
Email: agnesmejiamd@yahoo.com

On the 21st hospital day, she was intubated because of severe respiratory distress and was subsequently transferred to the medical ICU. On the 24th hospital day, she had fatal arrhythmia (ventricular tachycardia, then ventricular fibrillation) and was not revived after a total of 18 minutes of resuscitation. ETA gram stain obtained during intubation showed gram (+) cocci in pairs and gram (-) bacilli, and blood culture obtained one day prior to demise showed *S. Aureus*. Both results, however, were released postmortem (Table 4).

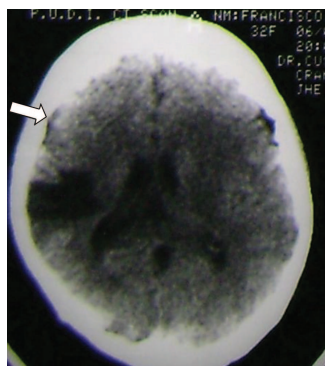


Figure 1A. Cranial CT Scan showing right temporoparietal cortical and subcortical hypodense lesion corresponding to the patient's first CVD

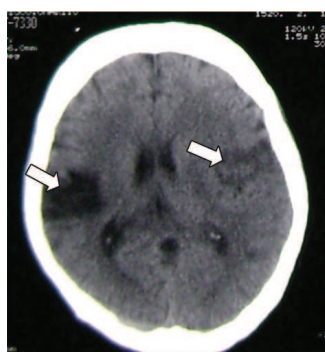


Figure 1B. Cranial CT Scan on admission. Well defined hypodensity on the right temporoparietal area; fairly defined hypodensity on the left temporal area. Impression: chronic infarct, right temporoparietal region; subacute infarct, left temporal region.

Final Clinical Diagnosis

Multiorgan failure secondary to sepsis secondary to pneumonia and catheter-related UTI (*Alcaligenes faecalis*)
 Secondary hypertension
 t/c primary aldosteronism
 t/c renal artery stenosis
 Renal tubular acidosis type I
 s/p CVD infarct, right temporoparietal and left temporal regions

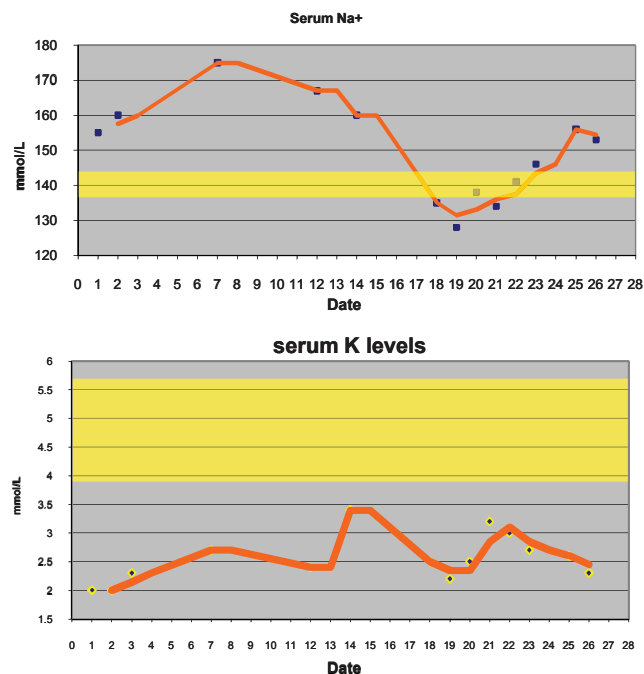


Figure 2. Serial sodium and potassium

Discussion

Our patient presented with hypertension at the young age of 23. She had suffered from two cerebral infarcts (at 37 and 38 years old), had cardiomegaly and atrial fibrillation at 32 years of age and persistent hypokalemia throughout her medical illness until the time of demise. She eventually succumbed to sepsis and acute kidney injury. This paper will discuss secondary hypertension. An autopsy was done which defined the etiology of her hypertension and cause of death.

Among the identifiable causes of hypertension in our patient, the following will be discussed, being the more common etiologies seen worldwide:

- Primary aldosteronism (PA)
- Renovascular Disease
- Kidney Disease
- Pheochromocytoma

Primary Aldosteronism (PA)

In the past, most clinicians considered primary aldosteronism to be a rare form of hypertension. Nowadays, it is recognized as a common form of secondary hypertension. It affects 5–13% of patients with hypertension.¹ Initially, hypertension associated with primary aldosteronism was considered mild and readily controlled as well as rarely with complications. However, several authors reported case series of PA with severe to malignant hypertension, or with marked target organ damage affecting the heart, carotid artery, or the kidney. Other studies noted an increased prevalence of cerebrovascular diseases in PA.² Rossi et al. reported that, in

patients with PA, the excess aldosterone could be associated with a pressure-independent remodelling of the left ventricle.³

Table 1. Complete Blood Count

	Reference Range	Day 1	Day 13	Day 17	Day 21
Hematocrit	0.37-0.54	.371	0.363	0.263	0.276
Hemoglobin (g/L)	120-180	104	105	81	86
White-cell count (10 ⁹ /L)	4.0-11.0	9.43	7.11	9.5	11.72
Differential count					
Neutrophils	0.50-0.70	.849	0.78	0.95	0.956
Lymphocytes	0.20-0.50	.128	0.04	0.033	0.031
Monocytes	0.02-0.090	.021	0.0	0.011	0.008
Eosinophils	0.00-0.06	0.0	0.0	0.002	0.002
Mean Corpuscular Volume (fL)	80-100	73.2	72.6	66.8	72.4
Mean Corpuscular Hemoglobin (pg)	27-31	20.5	21	20.6	22.6
Mean Corpuscular Hemoglobin concentration(g/L)	320-360	280	289	308	312
RBC count (10 ¹² /L)	4-6	5.07	5.0	3.94	3.81
Platelet count (10 ⁹ /L)	150-450	294	63	185	

Patients with hypertension and hypokalemia, treatment-resistant hypertension (three anti-hypertensive drugs and still with poor control), severe hypertension (≥ 160 mmHg systolic or ≥ 100 mmHg diastolic), hypertension with an incidental adrenal mass, onset of hypertension at a young age or patients being evaluated for other forms of secondary hypertension should undergo screening for primary aldosteronism.¹

In a retrospective study done at the Philippine General Hospital from 1993-2000, majority of patients with primary hyperaldosteronism presented with symptoms resulting from hypokalemia rather than from hypertension; the most common presenting symptom was generalized muscle weakness (32.26%), followed by headache (19.35%). Periodic paralysis was seen in 3.22% and stroke/TIA was seen in 6.45%. Laboratory examinations showed abnormal ECG findings in 70.60%, signs of hypokalemia in 11.76% (e.g. presence of u waves, flattening of T waves), benign premature ventricular contractions (PVC), left ventricular hypertrophy in 17.65% and a combination of signs of

hypokalemia and LVH in 41.18%. None presented with atrial fibrillation. All the patients were hypokalemic with a mean serum K⁺ of 2.46 ± 0.41 mEq/L (range 1.8–3.3 mEq/L). Only 11/17 had available serum Na⁺ results; of these, 1/11 was slightly hyponatremic while the rest were within the normal range. Arterial blood gas results were available in only seven patients; two had normal results while the rest had metabolic alkalosis.⁴

Table 3. Arterial Blood Gas

Arterial blood gas	Day 1	Day 19	Day 23
Ph	7.404	7.43	7.22
pCO2	26.7	12.2	23.6
pO2	97	156	108
HCO3	16.9	8.2	9.8
TCO2	17.7	8.5	10.5
BEb	-5.6	-13.4	-15.6
O2 sat	97.7	99.5	97.2

In another retrospective study done at Sto. Tomas University Hospital, of the nine patients confirmed to have primary aldosteronism, eight had weakness of extremities as the presenting symptom and one patient complained of headache. The mean baseline serum K⁺ level was 2.3 mEq/L (range: 1.9–3.0 mEq/L).⁵

Hypertension, hypokalemia, hypernatremia and absence of edema due to aldosterone escape phenomenon favor primary aldosteronism in this case. However, the patient's arterial blood gas showed metabolic acidosis instead of alkalosis. Metabolic alkalosis and elevation of serum bicarbonate are caused by hydrogen ion loss into the urine and migration into potassium depleted cells. The alkalosis is perpetuated by potassium deficiency, which increases the capacity of the proximal convoluted tubules to reabsorb filtered bicarbonate.⁶ On imaging, our patient had no adrenal mass; no enlargement was noted. Screening should include plasma aldosterone concentration and plasma renin activity.

Since she had persistent hypokalemia and hypernatremia with metabolic acidosis, other causes were considered.

Table 2. Blood Chemistries

Test	Reference Range	Day 1	Day 12	Day 16	Day 17	Day 18	Day 19	Day 20	Day 22	Day 23
Glucose	3.9-6.1 mmol/L	7.16								
BUN	2.6-6.4 mmol/L	4.09		33.37		38.52	43.34	44.50	29.26	27.71
Creatinine	53-115 umol/L	146	189	671	675	641	726	697	424	391
Na+	140-148 mmol/L	155	160	135	126	134	141	146	156	153
K+	3.6-5.2 mmol/L	2.0	3.4	2.5	2.2	3.2	3.0	2.7	2.6	2.3
Cl -	100-108 mmol/L	111					108	111	121	117
Calcium	2.12-2.52 mmol/L	2.56		1.86						
Mg	0.7-1.0 mmol/L	0.99		0.99						
Albumin	34-50 g/L	44		21						
HDL	0.91-1.56 mmol/L	1.3								
LDL	1.10-3.8 mmol/L	4.4								
Triglyceride	0.34-1.7 mmol/L	0.75								
Cholesterol	4.2-5.2 mmol/L	6.02								

Table 4. Other pertinent examinations

Thyroid function tests	FT4 : 18.4 TSH : 0.5
Ultrasound of kidneys and urinary bladder	Both kidneys exhibit increased parenchymal echogenicity with poor corticomedullary differentiation. Right kidney measures : 10.6 x 4.1 x 4.9 cm A cystic focus measuring 0.9 cm is seen in its inferior pole Left kidney measures: 7.3 x 4.4 x 4.4 cm Multiple high intensity echoes are seen surrounding the calyces and within the medullary regions. Punctuate high intensity echoes with posterior shadowing are likewise seen within the calyces. The urinary bladder is partially distended with irregularly thickened walls. Impression : bilateral medullary nephrocalcinosis with calyceal stones, contracted left kidney, bilateral diffuse parenchymal disease Cystitis considered
2D Echocardiography with Doppler studies	Concentric left ventricular hypertrophy with good wall motion and contractility and preserved overall systolic function, dilated left atrium, mitral regurgitation mild, tricuspid regurgitation mild, pulmonary regurgitation, moderate pulmonary hypertension, minimal pericardial effusion.
Urinalysis	Day 1 Light yellow, clear, specific gravity: 1.010, pH:7.0, sugar (-), protein (-), RBC 50-60, WBC 1-2, RBC morphology 100% normal Day 23 Yellow, hazy, specific gravity 1.005, pH:7.0,(-)sugar, (-) protein, RBC 0-2, WBC 30-40, coarse granular cast 0-1, amorphous phosphate +2, few epithelial cells, bacteria +4, few mucus threads
24 hr urine collection	Day 16 Total volume : 1750 Crea : 0.379 g/24 hrs Total protein : 5.536g/24 hrs
Urine culture and sensitivity	Day 21 (+) <i>Alcaligenes faecalis</i> ; sensitive to Cefepime, intermediate to Ceftriaxone
Blood culture and sensitivity	Day 23 <i>Staphylococcus aureus</i> Sensitive to oxacillin, chloramphenicol, co-trimoxazole, clindamycin

Renovascular Hypertension (RVH)

Renovascular hypertension is defined as an elevated blood pressure caused by renal hypoperfusion, usually resulting from anatomic stenosis of the main renal artery resulting in activation of the renin-angiotensin system.⁷

Renal artery stenosis is present in 1–2% of hypertensive patients. Its cause in most young individuals is fibromuscular dysplasia, particularly in women under 50 years of age. Another cause is Takayasu's arteritis, which is a chronic, idiopathic, inflammatory disease that primarily affects large vessels, such as the aorta and its main branches. Epidemiologically, it is found mostly in female patients and is more prevalent in Asian and Latin American countries.⁸

In the Hypertension Clinic of PGH, among the causes of secondary hypertension, renovascular hypertension accounts for 24% of all cases, and Takayasu's arteritis makes up 57% of these renovascular diseases.⁹

Renovascular hypertension is suspected in the following circumstances:

- abrupt onset;
- resistant hypertension (on three-drug therapy with good compliance);
- abdominal or femoral bruits;
- acute rise in serum creatinine after initiation of an ACE inhibitor, AII receptor blocker or direct renin inhibitor;

- worsening of renal function with an Angiotensin II antagonist;
- flash pulmonary edema;
- hypotension after initiation of AII antagonist.

RVH should be suspected in the young with new onset of hypertension or in the elderly when previously controlled hypertension becomes resistant. In the elderly, the most common cause is atherosclerotic renal artery stenosis. In the Philippines, Takayasu's arteritis is the most common etiology of RVH in the young.

Clinical features of Takayasu's arteritis, as reported by Estrella, Flauta and Mejia are hypertension (65%), headache (46%), blood pressure and pulse discrepancy (44%), visual disturbance (31%) and chest pain (30%). Average age at the time of diagnosis was 26.5 years with 42% in the 21–30 year age group.¹⁰

In our patient, RVH was suspected because of the discrepancy in kidney size. However, she had no other features of RVH, specifically, Takayasu's Arteritis.

Chronic Tubulointerstitial Kidney Disease (CTIN)

While chronic glomerulonephritis often presents with bilateral small kidneys, chronic tubulointerstitial disease can present with a unilateral small kidney. Histopathologically, there is interstitial infiltration of inflammatory cells, then eventual fibrosis and tubular atrophy. Over time, there is

gradual deterioration of renal function. Most common causes are reflux nephropathy and obstructive uropathy.

The principal manifestations of CTIN are due to tubular dysfunction. Because of the focal nature of the lesions, the pattern of tubular dysfunction that results varies, depending on the site of injury. Edema usually is not present, and BP is normal or only mildly elevated in the early stages. Signs and symptoms of acute or chronic renal insufficiency become manifest later, when the disease is far advanced. Diagnosis is based on history, physical examination, laboratory and imaging tests.¹¹

While obstructive uropathy due to stones or strictures often presents with recurrent UTI, pyuria or flank pain (colic) or passage of stone, reflux nephropathy can be asymptomatic, presenting only with abnormal urinalysis (often pyuria).

Reflux nephropathy is a term used to describe coarse renal scarring of one or both kidneys associated with primary vesicoureteral reflux and urinary tract infection. In adults, prevalence of hypertension is 38–50%. The degree of reflux and renal scarring would appear to be related to the development of hypertension. Hypertension, when present, accelerates the progression of renal failure.¹¹

Chronic hypokalemia is frequent in tubulointerstitial disease. It may produce nephropathy with impaired urinary concentration and vacuolization of proximal tubular cells and occasionally of distal tubular cells in moderate to severe cases. Chronic interstitial inflammatory changes, fibrosis, and renal cysts have been found in renal biopsies of patients with hypokalemia of ≥ 1 month. Although hypokalemia is treatable, the structural damage, i.e., fibrosis, is irreversible.

In our patient, chronic tubulointerstitial disease could not be ruled out.

Pheochromocytoma

Pheochromocytomas are rare neuroendocrine tumors with a highly variable clinical presentation.¹² It is difficult to diagnose, as it either appears in asymptomatic form (17%) or manifests in a variable clinical pattern—considered the most significant internal-medicine diagnostic imitator's symptomatology.¹³

Clinical and biochemical manifestations are primarily due to circulating catecholamines and hypertension. Typical clinical manifestations are either sustained or paroxysmal hypertension, severe headaches, palpitations and sweating resulting from hormone excess. However, the presentation is highly variable and can mimic many other diseases.¹⁴ It is very important to consider this because if it remains untreated, it can be life threatening.

In general, the hypertension is paroxysmal in 48% of patients and persistent in 29%; 13% have normal BP. Symptoms typically include a sudden rise of BP with concurrent episodes of headache (80%), diaphoresis (70%) and palpitations (60%). The episodes usually last for minutes

or even hours; symptoms usually begin abruptly and subside quickly. These episodic paroxysms may not recur for months or may recur many times daily. Each patient tends to have a different pattern of symptoms with the frequency and severity of episodes usually increasing over time. This triad (headache, diaphoresis, palpitations) was found to have a sensitivity of 90.9% and a specificity of 93.8%. Other symptoms may include anxiety (50%), a sense of dread, tremor, or paresthesias,¹⁵ like a panic attack.

Hypocalcemia, diarrhea and elevated blood sugar may be noted if the pheochromocytoma also produces other hormones (calcitonin, vasoactive intestinal peptide, cortisol, somatostatin). Diabetes is usually due to inhibition of insulin secretion by catecholamines.¹³ Increased glucose and cholesterol with leukocytosis can be seen but are nonspecific.

Our patient presented with the classic history of headaches, palpitations, and diaphoresis associated with hypertension. She also presented with evidence of target organ damage which is very common in pheochromocytoma. Blood chemistry also showed increased fasting blood sugar and dyslipidemia. Her corrected calcium was normal.

It is very prominent in the history that she had several episodes of hypokalemia manifested by periodic weakness. Several case reports published showed the relationship of pheochromocytoma with hypokalemia.^{16,17,18,19,20} This can be due to the ability of pheochromocytomas, being derived from chromaffin cells of the APUD series, to secrete other peptide hormones whose effects can confuse the diagnosis and contribute to the diverse clinical manifestations of pheochromocytomas. Hypokalemia can result from the actions of such hormones. Adrenocorticotropin can, for example, be secreted, producing hypercortisolism; similarly, vasointestinal polypeptide (VIP) secretion can lead to hypokalemia, through gastrointestinal potassium loss due to watery diarrhea. Catecholamines, particularly adrenaline, can also directly cause hypokalemia through stimulation of beta2 receptors causing activation of the sodium-potassium ATPase in skeletal muscle and subsequent ionic shift of potassium.¹⁹

Open Forum

Dr. Raymond S. Alonso (Head, Dialysis Unit): When I get a patient with hypokalemia and hypertension, the first reflex response is "Are they related?" Let us look at the diseases with hypokalemia and hypertension: (1) Renal Artery Stenosis (RAS), (2) Primary aldosteronism. These two conditions are associated with one common factor—potassium spillage. Determination of 24-hr urine K would have been very helpful because it will let you know if your patient is a salt-waster. And all the IV and oral potassium supplements given cannot correct it unless you give spironolactone. It is the only way to keep the potassium that you gave to the patient inside the body.

If without life-threatening hypokalemia, get urine K before you do something. It's either low or high. If it's low, then look at arterial blood gas (ABG). You may have your hypokalemic periodic paralysis or thyrotoxic periodic paralysis. With these tests, we can already look at our differentials: primary aldosteronism and renovascular hypertension due to renal artery stenosis. If there is K spillage, you don't just give K supplement but also spironolactone.

We were probably thrown off by that metabolic acidosis and nephrocalcinosis. These two automatically give you a diagnosis of Renal Tubular Acidosis (RTA). However, the urine pH was not that alkalotic, the initial bicarbonate was not that low, so this might be an incomplete RTA. Incomplete RTA won't give you severe metabolic acidosis, and incomplete RTA does NOT give you nephrocalcinosis. It does not produce stones. In retrospect, there was metabolic alkalosis but it was overwhelmed by something else causing metabolic acidosis. Renal failure or sepsis may have caused it. My initial diagnosis was RTA, but now, in retrospect, it's either a primary aldosteronism or RAS. Primary aldosteronism: because of the prominent hypokalemia. The prominent symptoms of aldosteronism are not even hypertension and hypernatremia, it is the signs and symptoms of low potassium. Whereas in RAS, the low K is not that prominent compared to the hypertension—especially with flash pulmonary edema. I think this patient had something in the adrenal glands, either a primary aldosteronism or a pheochromocytoma, because of the predominantly low potassium.

Dr. Agnes D. Mejia (Chair, Department of Medicine and Section of Nephrology): Relevant in this case are: hypertension and long-standing hypokalemia in the presence of target organ damage. As a rule, if you have hypertension and hypokalemia dating back 15 years, these are my usual considerations: Primary Aldosteronism, Pheochromocytoma, Chronic Kidney Disease (in the form of tubulo-interstitial disease), thyroid dysfunction, renal artery stenosis (likely unilateral), and Liddle's syndrome.

Primary aldosteronism, while chronic, will usually not cause severe target organ damage because the culprit is aldosterone. Whereas in pheochromocytoma, which causes catecholamine excess and renal artery stenosis and CKD which both produce AII, the target organ damage is often severe compared with primary aldosteronism. This lady had very severe target organ damage in a span of 15 years. If this were hypokalemia alone, without hypertension, the differentials would be hypokalemic periodic paralysis due to: RTA, tubulointerstitial disease or thyroid disease. I think in this case we have ruled out thyroid dysfunction. I think this was most probably pheochromocytoma, chronic tubulointerstitial disease or renovascular hypertension.

I think renovascular hypertension cannot be excluded because of one kidney being small. However, I think the

cause of acute renal failure here is sepsis and not the use of captopril. Captopril will only increase serum creatinine if you have bilateral renal artery stenosis or unilateral renal artery stenosis and a decompensated contralateral kidney or you have a single kidney with a renal artery stenosis. Hypokalemia in unilateral renovascular disease is due to the potassium being excreted by the contralateral normal kidney. Sepsis most likely caused the acute renal failure. This patient came in with elevated serum creatinine and in the course of illness, also had elevated bilirubin and transaminases. Though the white count was not high, there was a predominance of neutrophils (95%) with stabs.

Dr. Alonso: Why did the patient go into arrest?

The answer is very simple: prolonged hypokalemia depleted not only the intravascular stores, but more especially the intracellular stores. Hypokalemia causes hyperexcitability of the cell and decreases its threshold for arrhythmias.

Dr. Mejia: This patient had chronic hypokalemia for 15 years and was still alive up to this last confinement. I think she died of sepsis.

Autopsy

Dr. Amado O. Tandoc III (Resident, Department of Pathology):

We received the body of a 38 year old female and external examination showed jaundice, icteric sclera and midline infraumbilical surgical scar.

On opening of the chest, there was note of pleural adhesions and pleural effusion amounting to 350 ml on the right and 600 ml on the left. There were mucopurulent exudates and submucosal hemorrhages in the trachea (Figure 3). The right lung weighed 480g and the left lung 300g. On examination, there were mucopurulent exudates from both lungs (Figures 4-5).

The heart was heavy at 420g (normal: 200–280g) with 150 mL of serous pericardial effusion. The coronary arteries did not show significant occlusion (<70% occlusion). On cut section, the left ventricular wall measured 1.6 cm, interventricular septum 1.6 cm and right ventricular wall 0.5 cm consistent with concentric left ventricular hypertrophy (Figure 6). There was no dilatation, no septal and valvular defects, no infarction and no thrombus.

On microscopic examination, there was myocyte hypertrophy, increased fibroblast activity and myocyte fiber disarray. On examination of the aorta, there was note of atherosclerosis. The liver showed central hemorrhagic necrosis and there was acute splenitis.

On examination of the urinary tract, the right kidney weighed 300g and the left kidney 180g (normal: ~150g). The renal arteries were patent. There was acute pyelonephritis, bilateral. On microscopic examination of the kidneys, findings were: diffuse tubular atrophy and interstitial

fibrosis, calcification, hyaline arteriosclerosis, focal intracapsular fibrosis and focal glomerulosclerosis (Figures 7-10). The urinary bladder showed hemorrhagic cystitis, acute (Figure 11).

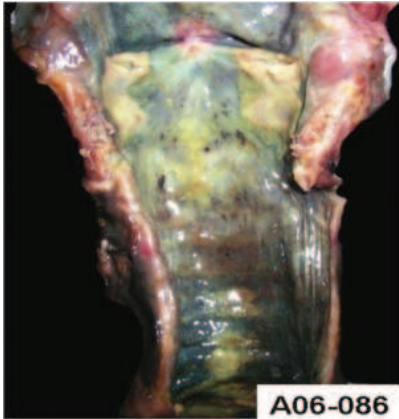

Figure 3. Trachea: mucopurulent tracheal exudates, submucosal haemorrhage

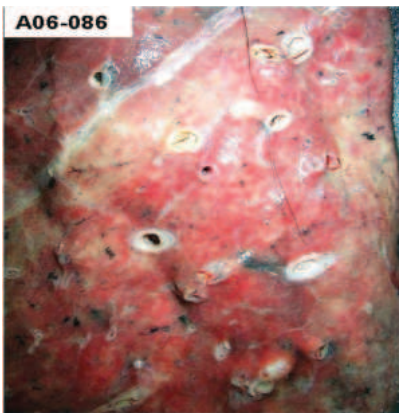


Figure 4. Right lung: mucopurulent exudate

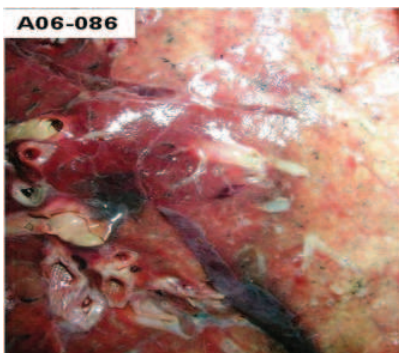


Figure 5. Left Lung: mucopurulent exudate

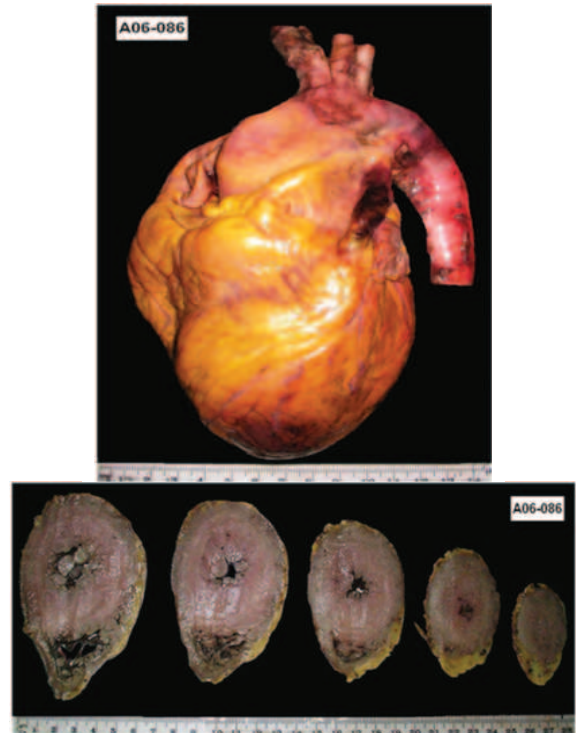


Figure 6. Cardiomegaly with concentric left ventricular hypertrophy.

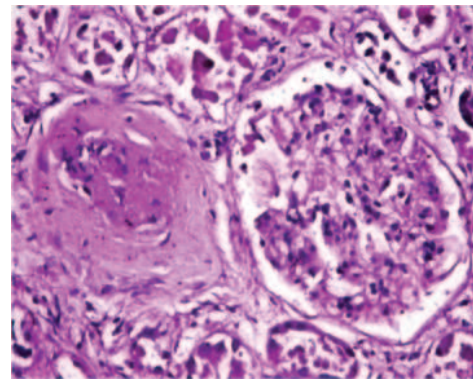


Figure 7. Kidney: hyaline arteriosclerosis

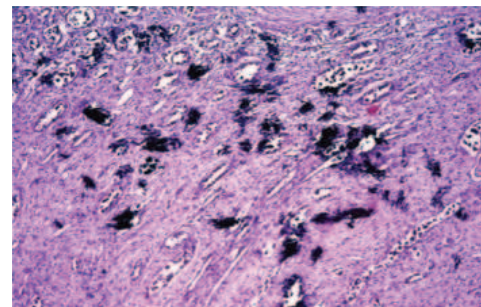


Figure 8. Kidney: calcification

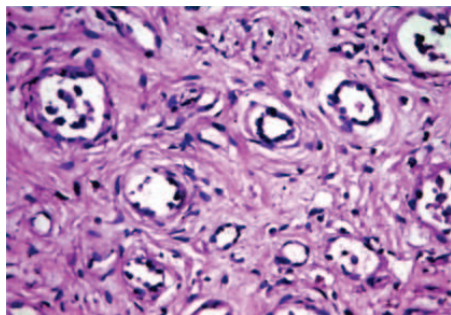


Figure 9. Kidney: diffuse tubular atrophy and interstitial fibrosis.

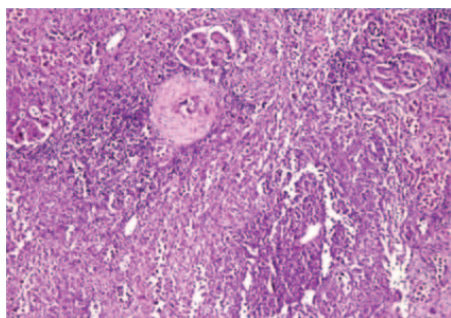


Figure 10. Kidney: acute inflammation

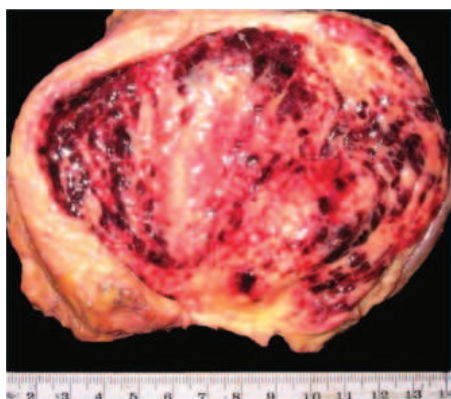


Figure 11. Urinary bladder: acute hemorrhagic cystitis.

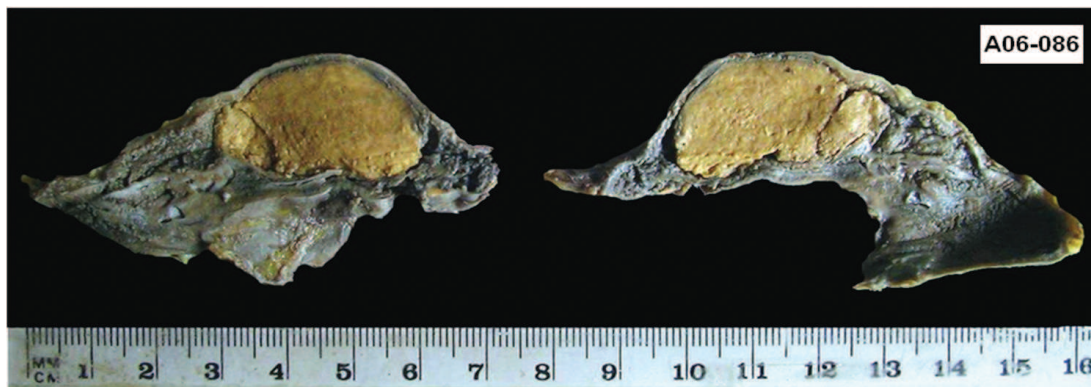


Figure 12. 3 x 2 x 1.5 cm tan to cream yellow, well circumscribed, soft to friable mass within the left adrenal gland

On examination of the adrenal glands, the right weighed 5.8g while the left weighed 8.0g. There was a 3 x 2 x 1.5 cm tan to cream yellow, well-circumscribed, soft to friable mass within the left adrenal gland which stained positive to chromogranin A (Figures 12 and 13). Thyroid examination was consistent with chronic lymphocytic thyroiditis.

The brain weighed 1,180 g. There was no gross evidence of herniation, bleed and exudates. On cut section, there was no midline shift, ventricular dilation, bleed or masses. There was a 3 x 2.5 x 2.5 cm irregular cavitation in the right temporoparietal region. There was a 2.5 x 2 x 1.5 cm irregular, ill-defined subcortical softening in the left temporoparietal region and a 1.5 x 1 cm ill-defined cortical-subcortical soft cavitated area, all consistent with non-hemorrhagic cortical-subcortical cerebral infarcts, old (right middle cerebral artery distribution) and recent (left middle cerebral artery distribution).

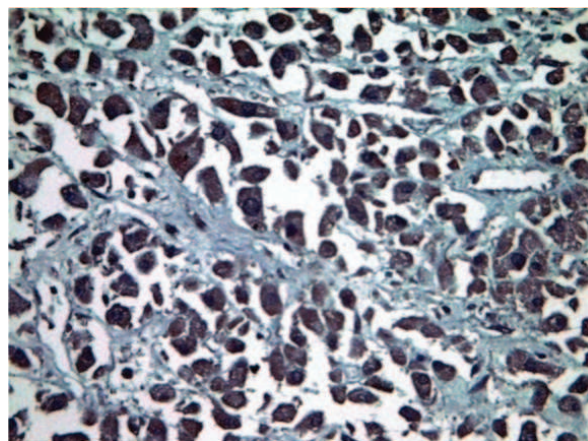


Figure 13. Left adrenal gland mass: Chromogranin A staining.

Final Anatomic Diagnosis

I. MULTIORGAN FAILURE SECONDARY TO SEPSIS: Alcaligenes faecalis (urine C/S), Staphylococcus aureus (blood C/S, result post mortem)

- A. ACUTE PYELONEPHRITIS, BILATERAL.
- B. ACUTE HEMORRHAGIC CYSTITIS.
- C. BRONCHOPNEUMONIA.
 1. PULMONARY CONGESTION AND CONSOLIDATION (480 GRAMS, RIGHT; 300 GRAMS, LEFT).
 2. PLEURAL EFFUSION (350 mL, RIGHT; 650 mL, LEFT).
 3. DIFFUSE PLEURAL ADHESIONS (R > L).
 4. ACUTE TRACHEOBRONCHITIS.
- D. CENTRAL HEMORRHAGIC NECROSIS, LIVER.
 1. JAUNDICE/ICTERISIA.
- E. ACUTE SPLENITIS.
 1. JAUNDICE/ICTERISIA.

II. PHAECHROMOCYTOMA, LEFT.

- A. HYPERTENSIVE CARDIOVASCULAR DISEASE.
 1. CARDIOMEGALY (420 GRAMS) WITH CONCENTRIC LEFT VENTRICULAR HYPERTROPHY.
 2. BENIGN NEPHROSCLEROSIS.
 - A. FOCAL SEGMENTAL GLOMERULOSCLEROSIS.
 - B. FOCAL INTRACAPSULAR FIBROSIS.
 - C. HYALINE ARTERIOLOSCLEROSIS.
 - D. DIFFUSE TUBULAR ATROPHY AND INTERSTITIAL FIBROSIS.
 3. CEREBRAL EDEMA (1180 GRAMS) WITH NON-HEMORRHAGIC CORTICAL-SUBCORTICAL CEREBRAL INFARCTS: OLD (RIGHT MIDDLE CEREBRAL ARTERY DISTRIBUTION) AND RECENT (LEFT MIDDLE CEREBRAL ARTERY DISTRIBUTION).

III. ATHEROSCLEROSIS.

- A. AORTA, MODERATE.
- B. CORONARY ARTERIES (<70 % OCCLUSION)
- C. RENAL ARTERIES (<70% OCCLUSION)

IV. CHRONIC LYMPHOCYTIC THYROIDITIS.

V. MIDLINE ABDOMINAL SCAR (S/P LOW SEGMENT CS).

CAUSE OF DEATH: SEPSIS.

References

1. Young WF. Primary aldosteronism: renaissance of a syndrome. Clin Endocrinol (Oxf). 2007; 66(5):607-18.
2. Milliez P, Girerd X, Plouin PF, Blacher J, Safar ME, Mourad JJ. Evidence for an increased rate of cardiovascular events in patients with primary aldosteronism. J Am Coll Cardiol. 2005; 45(8):1243-8.
3. Rossi GP, Sacchetto A, Visentin P, et al. Changes in left ventricular anatomy and function in hypertension and primary aldosteronism. Hypertension. 1996; 27(5):1039-45.
4. Jimeno C, Acampado L. Clinical profile of patients with primary hyperaldosteronism admitted to the University of the Philippines-Philippine General Hospital from 1993-2000. Philippine J Intern Med. 2004; 42:9-15.
5. Doroin Y, Gomez H, Mercado-Asis L. Clinical Profile of patients with primary hyperaldosteronism secondary to adrenal adenoma. Philippine J Intern Med. 2003; 41:18-22.
6. Williams G, Dluhy R. Disorders of the Adrenal Cortex. In: Fauci A, Braunwald E, Kasper D, Hauser S, Longo D, Jameson JL and Loscalzo J, eds. Harrison's Principles of Internal Medicine, 17th ed. New York: McGraw-Hill; 2008. p. 2260.
7. Taylor A, et al. Society of Nuclear Medicine Procedure Guideline for Diagnosis of Renovascular Hypertension. Society of Nuclear Medicine Procedure Guidelines Manual. August 2003: 97-104.
8. Zumrutdal A, Tercan F, Oguzkurt L, Sezer S, Nurhan Ozdemir F. Report of a case with surprising etiology of renovascular hypertension. Clin Nephrol. 2005; 64(6):444-7.
9. Dominguez-Mejia A, Cabotaje-Crisostomo A, Flauta J. SLE in a patient with Takayasu's arteritis. Philippine J Intern Med. 1999; 37:139-42.
10. Estrella A, Flauta J, Dominguez-Mejia A, et al. Takayasu's arteritis: A review of clinical features. Philippine J Intern Med. 1999; 37:19-24.
11. Dillon MJ, Goonasekera CD. Reflux Nephropathy. J Am Soc Nephrol. 1998; 9(12):2377-83.
12. Lenders JW, Eisenhofer G, Mannelli M, Pacak K. Pheochromocytoma. Lancet. 2005;366(9486):665-75.
13. Balazovjeh, I, Davidova H, Breza J. Restrospective analysis of patients clinical manifestations before and after pheochromocytoma surgery. Bratisl Lek Listy. 2004; 105(2):72-7.
14. Reisch N, Peczkowska M, Januszewicz A, Neumann HP. Pheochromocytoma: presentation, diagnosis and treatment. J Hypertens. 2006; 24(12):2331-9.
15. Karagiannis A, Mikhailidis DP, Athyros VG, Harsoulis F. Pheochromocytoma: an update on genetics and management. Endocr Relat Cancer. 2007; 14(4):935-56.
16. Linquette M, Decoulx M, Proye C, Gasnault JP, Racadot A, Benoit G. Pheochromocytoma with hypokalemia, hypercortisolism, hyperreninism and hyperaldosteronism: a case report. Lille Med. 1977; 22(9):665-9.
17. Gopel W, Schnabel D, Volger S, Grütters A. Severe Hypokalemia due to hyperreninemia and secondary hyperaldosteronism in a boy with pheochromocytoma. Eur J Pediatr. 1996; 155(2):147-8.
18. Nehaus T, Seewald S, Fronhoffs S, et al. 34 year old patient with headache attacks and hypokalemic hypertension. Internist (Berl). 1998; 39(6):650-4.
19. Smith JC, Meehan C, Lyons P, Robinson AM. A man presenting with limb weakness and electrolyte imbalance. Postgrad Med J. 1999; 75(889):691-3.
20. Grossman E, Knecht A, Holtzman E, Nussinovich N, Rosenthal T. Uncommon presentation of pheochromocytoma: case studies. Angiology. 1985; 36(10):759-65.