

# The Curious Case of Abdominal Dyskinesia: the Philippines' First Reported Case

Theodore Joseph J. Ablaza, MD<sup>1</sup> and Rhea Angela M. Salonga-Quimpo, MD<sup>2</sup>

<sup>1</sup>Department of Pediatrics, Philippine General Hospital, University of the Philippines Manila

<sup>2</sup>Department of Neurosciences, Department of Pediatrics, Division of Pediatric Neurology, Philippine General Hospital, University of the Philippines Manila

## ABSTRACT

This is a case of a 7-year-old Filipino female who presented with undulating movements of the abdomen that occur only while awake, following the initiation of treatment for clinically diagnosed pulmonary tuberculosis. Systemic physical examination was normal. The neurological examination was also unremarkable. The 2-hr video EEG showed no electroencephalographic changes or ictal pattern correlating with the abdominal dyskinesia, highly suggesting a movement disorder. Craniospinal Magnetic Resonance Imaging (MRI) with Gadolinium showed typical results. The patient responded to the trial of carbamazepine after three weeks of treatment with complete resolution of abdominal dyskinesia.

*Keywords: neurology, movement disorder, abdominal dyskinesia*

## INTRODUCTION

“Belly Dancer Dyskinesia” is a type of movement disorder that has been rarely reported in the literature. Anton van Leeuwenhoek first wrote this after his account in 1716.<sup>1</sup> Illiceto published a summary of five similar dyskinesia cases.<sup>2</sup> In 2011, Patterson presented a compilation of previous studies done amounting to 48 reported cases combining both the pediatric and adult population spanning from 1920 to 2011.<sup>3</sup> From 2012 onwards, there were approximately 12 more cases reported. Of these reports, only 5 were pediatric patients. Currently, there is limited study regarding this condition, and our patient would be the first reported case from the Philippines.

## CASE PRESENTATION

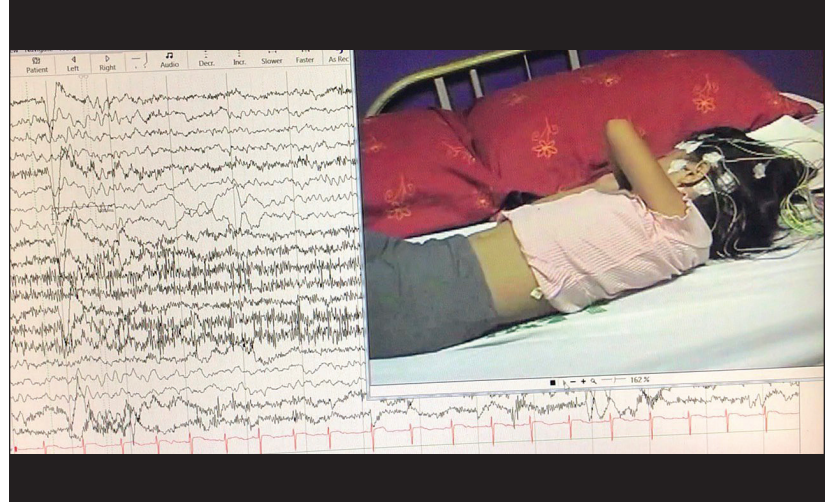
The patient is a seven-year-old Filipino female who presented with semi-rhythmic undulating abdominal movements described as “waving motions” one week after taking anti-tuberculosis medications to diagnose reactivation of pulmonary tuberculosis (Figure 1). These episodes occurred approximately once every three seconds lasting over 30 minutes to as long as six hours. The attacks would appear suddenly, but the patient remained awake during the episodes. No associated symptoms such as dyspnea or fatigue were reported. There were also no changes in breathing patterns and respiratory effort. Occasionally, the pain was elicited from the area below the subcostal margin of the right abdomen after prolonged movement. No vomiting episodes nor changes in bowel movement patterns were

*Paper won 1<sup>st</sup> place in Case Reports on October 2020, in the Department of Pediatrics, Philippine General Hospital, Manila Philippines.*

Corresponding author: Theodore Joseph J. Ablaza, MD  
Department of Pediatrics  
Philippine General Hospital  
University of the Philippines Manila  
Taft Avenue, Ermita, Manila 1000, Philippines  
Email: tjablaza@gmail.com



**Figure 1.** Screenshot of a video showing the undulating abdominal movements. The patient was awake and fully aware of the movements.



**Figure 2.** This shows the EEG clip during the 2-hour Video EEG. There was no electrographic seizure pattern during the episode of abdominal dyskinesia. Movement and EMG artifacts were seen.

noted. No additional adverse effects have been reported aside from dyskinesia.

The patient was previously treated for primary tuberculosis at five years old, where she completed a 6-month treatment. Her family and birth, and maternal history were non-contributory.

During the time of examination, the patient had normal vital signs. Chest examination revealed symmetric expansion, clear breath sounds, and absence of retractions. Abdominal findings showed non-distended, soft, non-tender abdomen, tympanic on percussion, normoactive bowel sounds, no mass palpated, liver not enlarged, Traube's space not obliterated (no movement at the time of examination), no hypertrophy of muscles or increased tone. Chest and abdominal examination findings were essentially normal. Systemic PE was unremarkable. A thorough and complete neurologic examination was done, which revealed typical results.

### Investigations

Due to the patient's primary presenting symptom of undulating abdomen movements, several investigations were done, including serum examinations, imaging studies, and electroencephalogram (EEG) to rule out other possible etiologies. Complete blood count was not suggestive of any active infection. Serum chemistry did not reveal any metabolic abnormalities. Chest and abdominal radiograph studies showed unremarkable findings.

Considering a possibility of a lesion from the brain down to the spinal cord which may cause abnormal abdominal movements, an imaging study was requested. Cranial and spinal Magnetic Resonance Imaging (MRI) studies revealed typical results. There was no mass, no inflammation, myelopathy, vertebral or vascular anomaly, or

other problems in intradural structures. With epilepsy as a differential, a two-hour video EEG was performed, which did not show any epileptiform abnormalities and absence of electrographic correlates while capturing the multiple clinical events of abdominal dyskinesia. The video EEG findings support that the movements were not epileptic and more consistent with a movement disorder.

Figure 2 shows the EEG tracing during an episode of abdominal dyskinesia. Diaphragmatic fluoroscopy was also done, which revealed no diaphragmatic flutter with the normal movement of the chest abdomen and diaphragm during inspiration and expiration.

### Differential Diagnosis

Our pediatric case presenting with continuous isolated abdominal movements termed "Belly Dancer Dyskinesia" can have several differential diagnoses.

Rhythmic abdominal movements can be seen in focal epilepsy, such as *Epilepsia partialis continua*. The patient presented with unrelenting focal onset seizures with retained awareness that occurred in different periods. This particular condition may manifest in one specific body part but may be associated with postictal confusion and weakness while preserving consciousness.<sup>4</sup> Despite observations of continuous movements that lasted as long as 6 hours, the patient never experienced weakness. In epilepsy, the seizure episodes may occur during wakefulness and sleep, whereas in movement disorders such as abdominal dyskinesias, attacks do not happen in sleep. This is the case in our patient, where the abdominal movements only occurred when awake. In focal epilepsy, EEG may show interictal epileptiform discharges and electrographic seizure patterns during the episodes. In our case, however, no epileptiform discharges

of any kind have been recorded and no electrographic seizures correlated with the abdominal movements.

Tardive Dyskinesia (TD) can also present with involuntary movements of specific body parts such as truncal musculature, usually associated with blockade of dopamine receptors as in chronic exposure to antipsychotics.<sup>5</sup> A thorough history made in our patient revealed only intake of anti-tuberculosis medications. Specific medications such as metoclopramide have been associated with TD. The patient had no exposure to such medicines.

Another condition that could be considered a differential in our patient is the Rippling Muscle Disease.<sup>6</sup> This disease involves proximal muscles, especially thighs. Visible ripples can be seen across the muscle lasting 5 to 20 seconds as described. This phenomenon requires overgrowth of muscles that were not present in our patient despite undulating abdomen movements for three months.

### Treatment

Treatment options for Belly Dancer Dyskinesia, with its rarity, especially in the pediatric population, has not been thoroughly studied. Several treatment strategies have been employed in published cases. Most of the treatments have depended on trial medications given by the attending physician. Although not considered a type of epilepsy, antiepileptic drugs have been started on some patients, such as carbamazepine, phenytoin. Haloperidol, a typical antipsychotic medication, has also been used to treat this condition. Due to this condition's rarity, Walton specified that treatment mainly comes from previous case reports and physicians' opinions.<sup>7</sup> Our patient underwent a trial of clonazepam for two weeks initially, but this did not alter the patient's symptoms. The medication was subsequently shifted to carbamazepine after which, complete resolution of the abdominal dyskinesia was observed after three weeks of treatment.

Some physicians have used diazepam as a form of treatment with favorable results.<sup>8</sup> Another study involving an 86-year-old who had a 1-year history of abdominal movement used clonazepam with a noted reduction in the movements.<sup>9</sup>

Deep Brain Stimulation has been used in cases thought to be resistant to medical treatment.<sup>10</sup> Another treatment that has been explored is botulinum toxin with favorable results, however, with the dangers of paralyzing the diaphragm completely. This has been reported in at least four cases, where Botox was administered using ultrasound guidance.<sup>11</sup> Although the various forms of treatment have proven effective for different instances, it has also been observed that spontaneous remission can occur without any active intervention.<sup>3</sup>

### Outcome and Follow-up

Our case of abdominal dyskinesia in a 7-year-old female was resolved after three weeks of treatment with

carbamazepine. A trial of clonazepam was initially done, but the patient did not respond. Botulinum toxin injection and deep brain stimulation were not considered in the patient since she responded to carbamazepine. These treatment modalities are costly and are difficult to obtain in our setting due to financial limitations.

On follow-up at one month, there was no recurrence of abdominal dyskinesia. Carbamazepine was discontinued a month following the complete resolution of the symptoms. Follow-up was done at three months, and the patient remained symptom-free. Written consent was obtained for the publication of the case.

## DISCUSSION

Abdominal dyskinesia has remained an area of interest and study from the first time Leeuwenhoek reported in 1716.<sup>1</sup> Following Iliceto's presentation of 5 cases in 1990, only a handful of pediatric patients registered have been reported worldwide.<sup>2</sup> In 2012, Coelho suggested that Arnold's Reflex was related to the abdominal dyskinesia seen in a 14-year old following note of repetitive ear infections and a subsequent tympanostomy.<sup>12</sup> In 2013, Panigraphy et al. described respiratory flutter in a neonate in India, making it the 8<sup>th</sup> reported case in an infant to date.<sup>13</sup> Moreira in 2017 presented a case of abdominal dyskinesia in a 14-year-old female following a fall injury.<sup>14</sup> No similar reports have been published yet in the Philippines.

Several etiologies have been implicated as triggers for undulating movements in literature. Trauma in the form of a fall accident in an adolescent and a sports injury following a Pilates' exercise in an adult was recorded.<sup>14,15</sup> Surgery has been thought of as a possible factor as well as in the case following ear surgery and hemorrhoidectomy.<sup>12,16</sup>

Metabolic derangements such as hyponatremia and its consequence of myelinolysis have also been reported.<sup>17</sup> The pathophysiology for these has not been understood.

As in our case, studies have described onset following intake of medications. In a reported case in Spain, sudden abdominal pulsations were noted in an 80-year-old after a 2-week intake of Galantamine for Alzheimer's Disease. Cessation of the drug caused the coinciding termination of the abdominal movement.<sup>18</sup> In India, a 23-year-old male, presented with a two-month history of anterior abdominal wall undulating movements that first appeared two days after intake of domperidone for acute gastroenteritis.<sup>8</sup> Another case report in Spain involved chronic use of clobopride associated with the appearance of abdominal dyskinesia in a 52-year-old after taking the said medication for five years for digestive problems.<sup>19</sup> In a recently published article by Cavdar et al. about abdominal wall dyskinesia, a 68-year-old had abdominal wall movements for two weeks after the intake of prochlorperazine for nausea due to chemotherapy. Cessation of the medication caused complete resolution of the abdominal wall movements.<sup>20</sup> Since our

patient has taken anti-tuberculosis medications, a thorough search of the literature was done to look for similar cases. No prior literature has revealed any association between pyrazinamide, rifampicin, isoniazid, nor ethambutol with abdominal dyskinesia. This would be the first report to do so, although causality has not been established. There has also been no published data showing the association of any form of tuberculosis with undulating movements of the abdomen. Other neurologic manifestations aside from peripheral neuropathy have been rarely observed as well. In a case report by Wong and Tan, an account of an oculogyric crisis (OGC) was observed following intake of the prescribed daily dose of Isoniazid, Rifampicin, Pyrazinamide, and Ethambutol<sup>21</sup> described as a contraction of the extraocular muscle resulting in deviation of the eye.<sup>22</sup>

## LEARNING POINTS

1. Abdominal dyskinesia, particularly in the pediatric population, remains an area of interest for further study, given the rarity of the cases. Different etiologies have been implicated in the appearance, such as following medication intake, but no in-depth reviews have been published.
2. In a country where tuberculosis remains a public health issue, possible complications such as the occurrence of abdominal dyskinesia can be further investigated.
3. There is no established standard of treatment for this condition. Current treatment options range from intake of medication such as carbamazepine, which is readily available, to more invasive and costly ones such as botulinum toxin injection and deep brain stimulation. The choice of medicines, particularly in a developing country, would be affected by several factors such as the cost-effectiveness of the drug, availability, and safety.

## Statement of Authorship

Both authors participated in the data collection and analysis and approved the final version submitted.

## Author Disclosure

Both authors declared no conflicts of interest.

## Funding Source

The study was self-funded.

## REFERENCES

1. Larner A. Antony Van Leeuwenhoek and the Description of Diaphragmatic Flutter (Respiratory Myoclonus). *Mov Disord.* 2005 July; 20(8):917-8.
2. Iliceto G, Thompson P, Day B, Rothwell J, Lees A. Marsden C. Diaphragmatic Flutter, the Moving Umbilicus Syndrome, and "Belly Dancer's Dyskinesia. *Mov Disord.* 1990; 5(1):15-22.
3. Patterson V. Belly dancer's syndrome: Causes, Clinical Presentations, and Treatment. [Internet]. 2011 [cited 2021 Aug]. Available from: <http://www.logan.edu/mm/files/LRC/Senior-Research/2011-Dec-31.pdf>.
4. Khan Z, Arya K, Bollu P. Epilepsia Partialis Continua. [Internet]. 2020 [cited 2021 Aug]. Available from: <https://www.ncbi.nlm.nih.gov/books/NBK532275/>
5. Vasan S, Padhy R. Tardive Dyskinesia. [Internet]. 2021 [cited 2021 Aug]. Available from <https://www.ncbi.nlm.nih.gov/books/NBK448207/>
6. U.S. National Library of Medicine. Rippling Muscle Disease. [Internet]. 2014 [cited 2021 Aug]. Available from: <https://ghr.nlm.nih.gov/condition/rippling-muscle-disease>
7. Walton D, Bonello M, Steiger M. Diaphragmatic Flutter. *Pract Neurol.* 2017;0:1-3.
8. Gupta A, Kushwaha S. Belly Dancer's Dyskinesia: A Glimpse of a Rare Phenomenon. *Cureus.* 2017 Jul; 9(7): e1457
9. Chen R, Remtulla H, Bolton C F. Electrophysiological Study of Diaphragmatic Myoclonus. *J Neurol Neurosurg Psychiatry.* 1995 Apr; 58(4): 480-3.
10. Schrader C, Capelle H, Kinfe T, Krauss J. Pallidal Deep Brain Stimulation in Belly Dancer's Dyskinesia. *Mov Disord.* 2009; 24(11): 1698-1700.
11. Alshubaili A, Abou-Al-Shaar H, Santhamoorthy P, Attia A, Bohlega, S. Ultrasound-Guided Botulinum Toxin A Injection in the Treatment of Belly Dancer's Dyskinesia. *BMC Neurol.* 2016; 16(226).
12. Coelho M, Kyllerman M. Belly Dancer Syndrome. *Acta Paediatr.* 2012 September; 101(9):e386-e387.
13. Panigraphy N, Kumar, P, Chirla, D. Respiratory Flutter Syndrome in a Neonate. *Indian Pediatr.* 2013 February; 50:242-3.
14. Moreira A, Freitas A, Rocha F, Cardoso R, Fonseca P. Belly Dancer's Syndrome – a Diagnostic Challenge. *Nascer e Crescer – Birth and Growth Medical Journal.* 2017; 26(1): 49-52.
15. Cho H, Panyakaew P, Srivannichapoom P, Hallett M. A Case of Functional Belly Dancer's Dyskinesia. *Mov Disord Clin Pract.* 2016 May-Jun; 3(3): 306-8.
16. Amin OSM, Abdulkarim QH, Shaikhani M. Intermittent Bursts of Abdominal Wall Jerky Movements: Belly Dancer's Syndrome? *BMJ Case Reports* 2012; doi: 10.1136/bcr-2012-007393.
17. Roggendorf J, Burghaus L, Liu WC, Weisenbach S, Eggers, C, Fink G, Hilker R. Belly Dancer's Syndrome following Central Pontine and Extrapontine Myelinolysis. *Mov Disord.* 2007 April; 22(6):892-4.
18. Hernandez-Fernandez F, Pardo-Fernandez JM, Garcia-Martinez E, Segura T. Respiratory Myoclonus, a Side Effect of Galantamine. *Farm Hosp.* 2011 Mar-Apr; 35(2):97-9.
19. Linazasoro G, Blercom N, Lasa A, Fernandez J, Aranzabal I. Etiological and Therapeutical Observations in a Case of Belly Dancer's Dyskinesia. *Mov Disord.* 2005 February; 20(2): 251-3.
20. Cavdar L, Ajasin S, Woolf S, Fekete R. Abdominal Wall Dyskinesia: Case Report. *Case Rep Neurol.* 2020;12:69-72.
21. Wong L, Tan E. Anti-tuberculosis Medication-induced Oculogyric Crisis and the Importance of Proper History Taking. *Int Med Case Rep J.* 2017; 10:341-4.
22. Robottom BJ, Factor SA, Weiner WJ. Movement Disorders Emergencies Part 2: Hyperkinetic Disorders. *Arch Neurol.* 2011; 68(6):719-24.