

Management of a Patient with Angle Class I Malocclusion with Anterior Crossbite and Maxillary Central Diastema Caused by High Attachment of the Maxillary Labial Frenulum

Faradiah Hayati, DDS, Hanifa Aini, DDS and Ida Bagus Narmada, DDS, PhD, Ort

Department of Orthodontics, Faculty of Dental Medicine, Universitas Airlangga, Surabaya, Indonesia

ABSTRACT

Maxillary Central diastema is common and normal for the growth and development of the anterior segment. If the central diastema persists after the eruption of the permanent cuspids, the orthodontist should clarify the etiology and establish a treatment plan. This case report discusses a 22-year-old woman with anterior crossbite and central diastema due to a high maxillary labial frenulum attachment. Treatment was performed using a fixed orthodontic appliance with a posterior bite raiser. Frenectomy was performed at the end of the orthodontic treatment.

Key Words: central diastema, frenectomy, maxillary labial frenulum

INTRODUCTION

Angle Class I malocclusion is the most common malocclusion with a prevalence of more than fifty percent, characterized by normal anteroposterior molar relationship, which may or may not be accompanied by skeletal changes in the vertical or transverse planes or dental changes.^{1,2} Several clinical signs like crowding, proclination, median shift, open bite, deep bite, and diastema can accompany Angle Class I malocclusion.² During the last decade, the frequency has been high with varied clinical forms.³

Maxillary midline diastema is one of the most frequently seen malocclusions, with incidences ranging from 1.6% to 25.4% and inversely proportional to age.³ Angle and Sicher stated that an abnormal frenulum is a cause of midline diastema occurring in approximately 98% of 6-year-olds, 49% of 11-year-olds, and 7% of 12 to 18-year-olds. It is one of the growth characteristics during mixed dentition where the space is closed in most children when the lateral and canine teeth erupt.^{4,5} The continuing presence of a diastema between the maxillary central incisors in adults is often considered an esthetic or a malocclusion problem.⁴ A frenulum attached too close to the gingival margin can cause diastema, gingival recession, bone loss due to a muscle pull, and poor lip mobility, especially when smiling and speaking.⁶

The use of fixed appliances is generally needed to treat class I malocclusions. Advantages of using fixed orthodontic appliances over removable appliances include precise tooth control, multiple tooth movement in all three planes of space, and patient cooperation. The choice of the type of appliance and the need for extraction or not is assessed for each case.⁷

Paper presented in the Temu Ilmiah Nasional-Internasional ke-8 (TIMNASS 8) - Faculty of Dental Medicine, Universitas Airlangga on February 27-29, 2020 at Surabaya, Indonesia.

Corresponding author: Ida Bagus Narmada, DDS, PhD, Ort
Department of Orthodontics
Faculty of Dental Medicine
Universitas Airlangga
Surabaya, Indonesia
Email: dr_narmada@yahoo.com

Effective treatment of diastema requires an accurate diagnosis of its etiology and a treatment plan related to that specific etiology, including medical and dental histories, radiographic and clinical examinations, and probably tooth-size evaluations.⁸ Over the years, the relationship between the maxillary midline diastema and the labial frenulum has been the subject of much controversy and confusion.⁹ In the case presented, we described the etiology of midline diastema, the orthodontic treatment steps made, and the progress of the Angle Class I malocclusion with the fixed orthodontic appliance combined with frenectomy to remove the soft tissue that caused the diastema.

CASE REPORT

A 22-year-old woman came to the RSGM-P Orthodontics Department, Faculty of Dental Medicine, Airlangga University, with crossbite anterior and central diastema due to high attachment of the maxillary labial

frenulum. The patient had never had orthodontic treatment before and wanted to be treated to improve the appearance of her face and smile, especially the aesthetic of her teeth.

Extraoral examination showed convex face profile, medium face type, mesocephalic head shape, competent lips, normal speech function, and no bad habits (Figure 1).

Intraoral photographs revealed good oral hygiene with normal oral mucosa, tongue, and palate, with moderate caries frequency (Figure 2). There is mandibular anterior crowding. The sagittal relationship of the right and left canine was neutroclusion, while the right and left molar was neutroclusion. There was an overjet of -2 mm and an overbite of 2 mm, respectively. Dental cast analysis indicated a discrepancy of 4 mm in the upper arch, -3.5 mm in the lower arch with a 2 mm positive curve of spee.

Cephalometric analysis indicated that the patient has a convex profile with \angle NA-Apog value 10° and \angle FH-Npog 71.5° and as shown by her Rickett's and Steiner's upper and lower lip analysis. In relation to the cranium base, the



Figure 1. Patient's extraoral photographs.

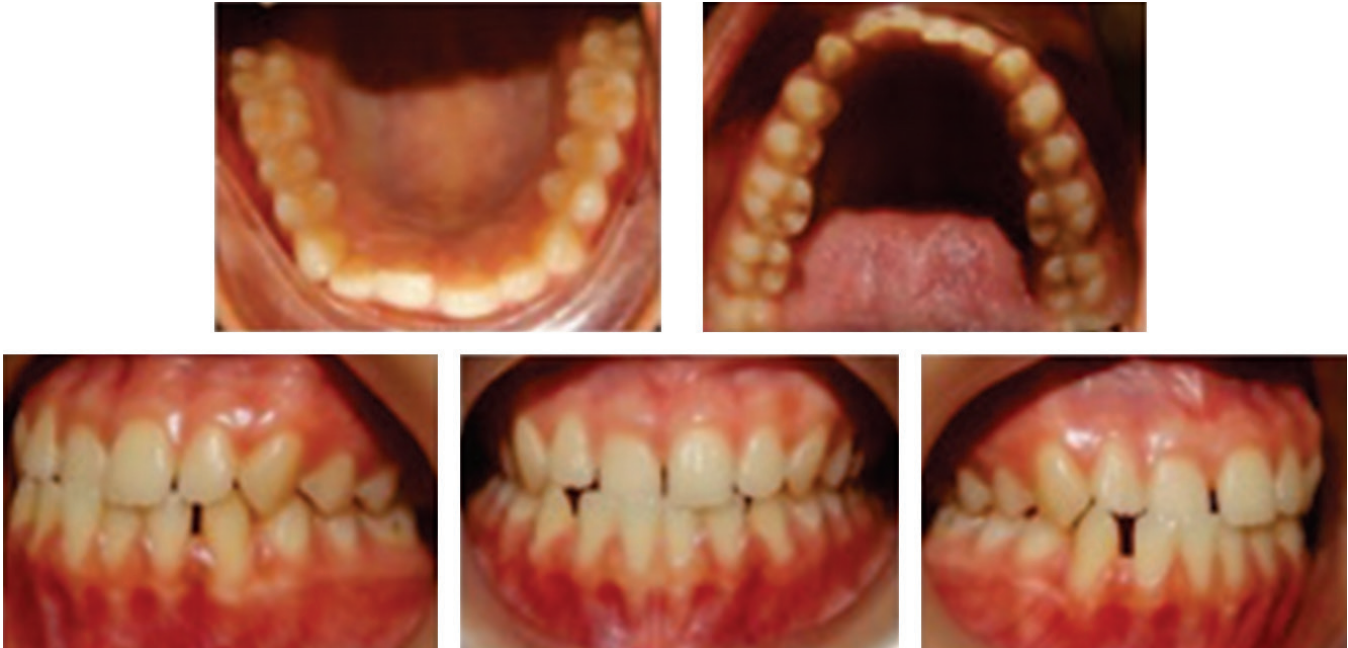

Figure 2. Patient's intraoral photographs pre-treatment.

maxilla and mandible showed a skeletal Class I relationship with a value of $\angle ANB$ 4° , and a Wits appraisal of 0 mm. The dental inclination of the maxillary incisors was upright with a value of $\angle I$ RA-NA 19° , and the mandibular incisors protrusive with a value of $\angle I$ RB-NB 32° , $\angle IMPA$ 102° , and $\angle FMIA$ 40° . Soft tissue analysis showed a convex profile with a value of $\angle GSn-SnPog'$ 17° , nasolabial $\angle 96^\circ$.

Diagnosis

Angle Class I malocclusion with anterior crossbite and maxillary central diastema.

Etiology

The main cause of the Angle Class I malocclusion, in this case, was a high attachment of the maxillary labial frenulum.

Treatment objectives

The treatment objectives were to correct the maxillary anterior crossbite, mandibular crowding, anterior maxillary and mandibular diastema, and maintain Class I relationship of the canines and molars with ideal arch form in the maxilla and mandible, with normal overjet and overbite.

Treatment plan

According to the information gathered from both clinical examination and diagnostic records, including dental and orthodontic history, photographs of the patient's face and teeth, clinical examination, dental casts, and radiograph photos, the clinician planned to use fixed orthodontic appliances accompanied with posterior bite raiser. In this case, a tooth extraction such as the premolar was not required. Frenectomy was performed after the orthodontic treatment.

Management

Medical record and informed consent were taken. Scaling was done as a preliminary treatment, and casts were taken for the dental study models. The molar bands were cemented to the upper and lower first molar. A 0.022-inch slot MBT (McLaughlin, Bennett, and Trevisi) were preadjusted edgewise. An appliance prescription (American Orthodontic) was selected and bonded to the upper and lower arches. Leveling and aligning began with 0.012 round Nickel-Titanium (NiTi) Archwire, followed by a 0.014 round NiTi Archwire for the upper and lower arches. A posterior bite raiser was made two months after bracket placement. The wire size was switched to Stainless-Steel (SS) recta 0.016 x 0.016 on the upper arch. The next phase was the retraction of the maxillary canines (13 and 23) and the closure of the upper and lower arch spaces. After 17 months of orthodontic treatment, the anterior crossbite and crowding in the upper and lower arch were corrected. In this phase, frenectomy was performed to eliminate the high attachment of the maxillary labial frenulum. Finishing and repairing the interdigitation were done (Figure 3).

DISCUSSION

Treatment of class I malocclusions aims to improve the aesthetics, the function of the teeth and jaw, such as correcting crowding so that a better dental arch relationship and crossbite are obtained.¹ In this case, the patient presented with an anterior crossbite and midline diastema caused by a high attachment of the maxillary labial frenulum.

Midline diastema is usually caused by factors such as iatrogenic, pathological and developmental problems.⁵

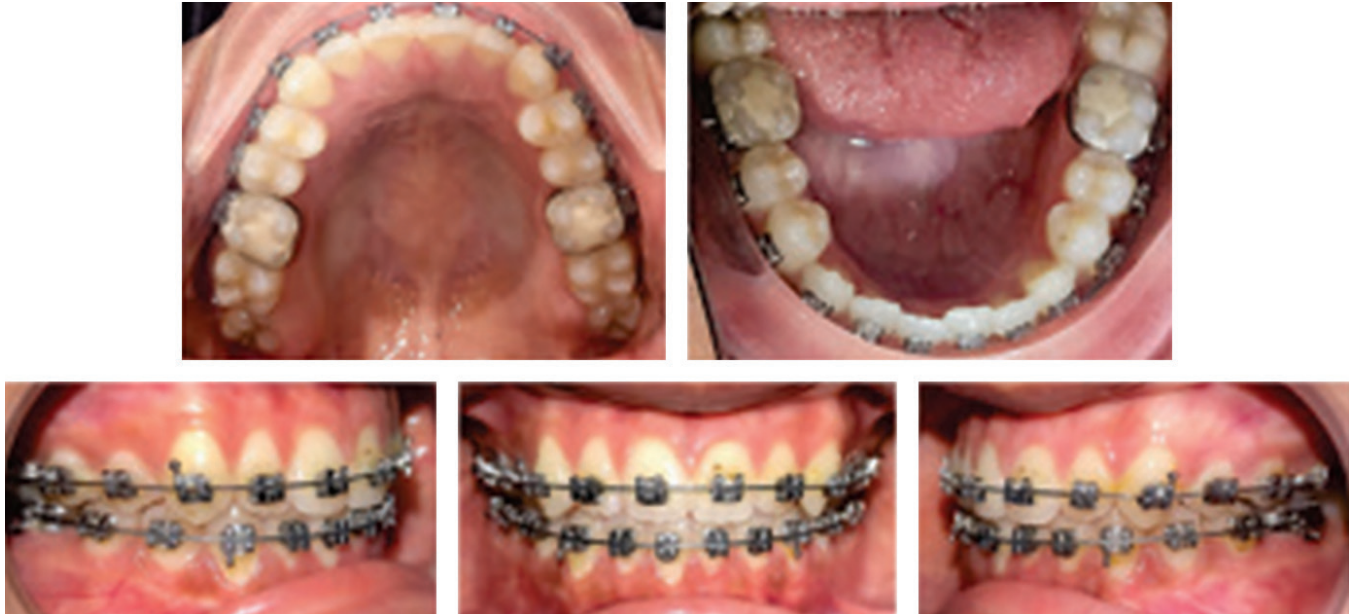

Figure 3. Patient's intraoral photographs during treatment.

A thick, wide maxillary labial frenulum attached close to the gingival margin is often considered a contributing factor for midline diastema and delayed growth of the premaxilla.⁶ The maxillary labial frenulum is a fold of tissue, usually triangular, extending from the maxillary midline area of the gingiva into the vestibule and mid-portion of the upper lip.⁹ The primary role of the frenulum is to provide stability to the upper lip and maintain a balance between the growing bones.⁶ An "abnormal" frenulum is clinically defined as a prominent tissue band with an attachment in the palatine papilla showing some blanching when tension or pull is exerted on it.¹⁰ Some disadvantages and disturbances that frenulum abnormality causes are diastema, abnormal position of the anterior central incisors, rapid dental caries, periodontal problems arising from food impaction, esthetic concerns, and upper lip damage.⁵

It is essential to decide how we manage each case to achieve the best result.⁷ The problem may be solved by extracting teeth in both arches or without extraction. The degree of the malocclusion and the number of teeth extracted also affect the treatment duration.⁷ In this case, the clinician chose a fixed orthodontic appliance after discussing and agreeing with the patient and considering her age with the permanent dentition phase.

Fixed orthodontic appliances are indicated whenever multiple tooth movement is required, such as intrusion, derotation, controlled space closure at the extraction sites, tooth bodily movement, extrusion, or torque control applied to this case.¹¹ By using 0.022 slots, the clinician could perform more freedom of movement of initial aligning arch wires in the relatively larger slot.¹² The MBT prescription was selected to reduce tipping of the anterior and upper posterior teeth and loss of molar anchorage. In addition, a reduction

in the tip of the canines has also been introduced in the MBT prescription to reduce the risk of cuspid and bicuspid roots coming close and allow the crowns to be placed in a slightly more upright position, thus reducing anchorage demand.¹³ This is a consideration because the canines, in this case, require retraction with optimal anchoring.

In patients with light crowding of anterior teeth need space, provided by interproximal reduction.¹² Dental casts analysis, in this case, showed that the discrepancy in the upper and lower arch was 4 mm and -3.5 mm, respectively. The clinician decided no need to do an extraction and opted for interproximal reduction to provide space for correcting mild crowding ($\leq 4\text{mm}$) in the mandible.

In patients with a crossbite, the use of the posterior bite riser would help unblock the bite while leveling and aligning is still in progress. After tooth 11 was jumped in front of teeth 41 and 42, the posterior bite riser was removed. Seventeen months later of orthodontic treatment, crossbite, a diastema, and crowding were successfully corrected, and the Class I relationship of canines and molars was maintained. A frenectomy was then performed.

Most orthodontists felt that the diastema should be closed orthodontically before frenectomy. If orthodontic treatment is indicated, they advise that frenectomy be performed only after the diastema is closed.¹⁴ This rationale is based on the hypothesis that granulation and scar tissue following frenectomy can interfere with the orthodontic treatment.¹⁰ This suggestion is in agreement that the clinician in this case also performs frenectomy after the diastema is closed. Frenectomy was performed to remove the high attachment of the maxillary labial frenulum, which was the leading cause of malocclusion in this case. After the mucosa is healed, orthodontic treatment ends with

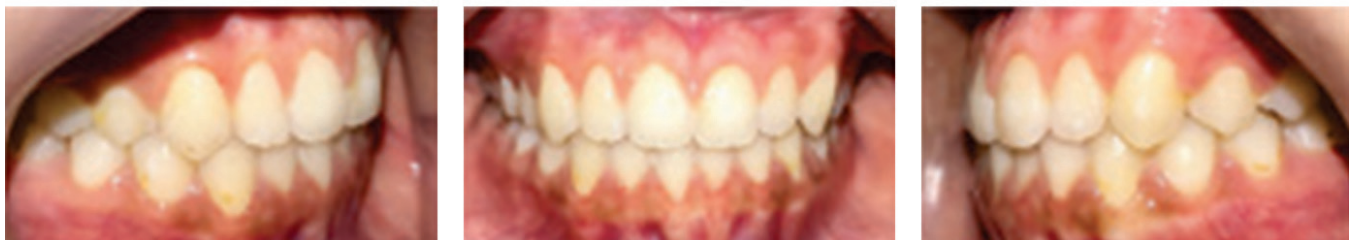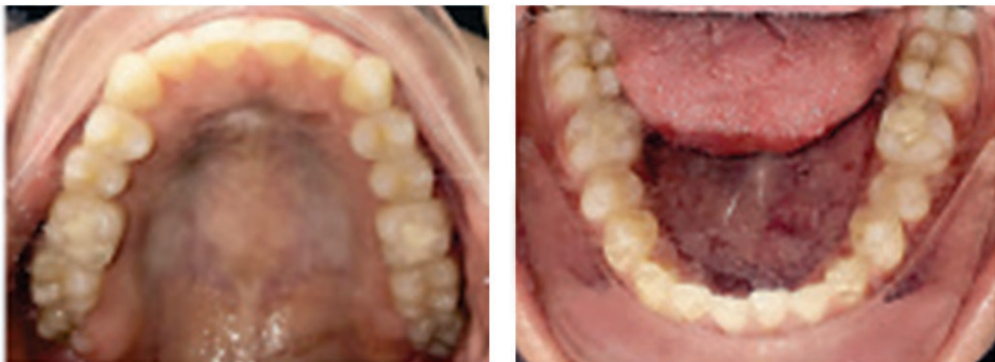



Figure 4. Patient's extraoral and intraoral photographs post-treatment.

finishing and detailing as the last step. The late control and busyness of the patient as a medical student at Airlangga University made her undergoing orthodontic treatment longer than usual. The total time of orthodontic treatment was 30 months (Figure 4).

CONCLUSION

This case showed that Angle Class I malocclusion with crossbite anterior and central diastema due to high attachment of maxillary labial frenulum treated with fixed orthodontic appliance combined with frenectomy yielded good results.

This case indicates that a suitable treatment plan can provide satisfactory progress. The main cause of the

malocclusion must be identified well before the start of the treatment. Selection of an appliance and an assessment needs in each case, such as selecting a bracket prescription, type of wire, techniques for leveling-aligning and space closure, and anchorage, must be prepared to obtain optimal orthodontic treatment results.

In this case, the clinician recommended performing frenectomy after diastema closure to prevent the appearance of postoperative scars that could interfere with orthodontic treatment or lead to relapse.

Acknowledgment

Our gratitude especially to the patient and RSGM-P Faculty of Dentistry, Universitas Airlangga, for their willingness to allow the photos to be presented.

Statement of Authorship

All authors participated in the data collection and analysis and approved the final version submitted.

Author Disclosure

All authors declared no conflicts of interest.

Funding Support

No funding support.

REFERENCES

1. Rahardjo P. *Ortodonti Dasar*. Surabaya: Airlangga University Press; 2009. pp. 50-1.
2. Silva I. Angle Class I malocclusion treated with extraction of first permanent molars. *Dental Press J Orthod*. 2010; 15(4): 133-43.
3. Abraham R, Kamath G. Midline Diastema and its Aetiology - A Review. *Dent Update*. 2014; 41: 457-464.
4. Hussain U, Ayub A, Farhan M. Etiology and treatment of midline diastema: A review of literature. *Pakistan Orthodontic Journal*. 2013; 5(1): 27-33.
5. Seraj B, Shahrabi M, Masoumi S, Jabbarian R, Manesh AA, Fini MB. Studying Maxillary Labial Frenulum Types and Their Effect on Median Diastema in 3-6-year-old Children in Tehran Kindergartens. *World J Dent*. 2019; 10(2): 93-7.
6. Rajani ER, Biswas PP, Emmatty R. Prevalence of variations in morphology and attachment of maxillary labial frenum in various skeletal patterns - A cross-sectional study. *J Indian Soc Periodontol*. 2018; 22(3): 257-62.
7. Alam MK, Nowrin SA, Shahid F, (max of 6 authors), et al. Treatment of angle class I malocclusion with severe crowding by extraction of four premolars: A case report. *J Med Sci*. 2018; 17(4): 683-7.
8. Kamath MK, Arun AV. Midline diastema. *Int J Orthod Rehabil*. 2016; 7: 101-4.
9. Jonathan PT, Thakur H, Galhotra A, Galhotra V, Gupta N. Maxillary labial frenum morphology and midline diastema among 3 to 12-year-old schoolgoing children in Sri Ganganagar city: A cross-sectional study. *J Indian Soc Pedod Prev Dent*. 2018; 36: 234-9.
10. Suter VGA, Heinzmann AE, Grossen J, Sculean A, Bornstein MM. Does the maxillary midline diastema close after frenectomy? *Quintessence Int*. 2014; 45(1): 57-66.
11. Singh G. *Textbook of Orthodontics*. India: Jaypee Brothers Medical Publishers (P) Ltd; 2004. p. 565.
12. Samawi SS. *Straight-Wire Orthodontics A Short Guide to Principles and Technique 1 st Edition* [Internet]. 2014 [cited 2019 Aug]. Available from <http://www.sdoc.jo/>.
13. Thickett E, Taylor NG, Hodge T. Choosing a pre-adjusted orthodontic appliance prescription for anterior teeth. *J Orthod* 2007; 34(2): 95-100.
14. Wheeler B, Carrico CK, Shroff B, Brickhouse T, Laskin DM. Management of the Maxillary Diastema by Various Dental Specialties. *J Oral Maxillofac Surg*. 2018; 76(4): 709-15.

The Acta Medica Philippina is now accepting original scientific papers, review articles and case reports for its upcoming issues. Please follow the format for submission as indicated in the "Instructions to Authors" elsewhere in the journal.

**All papers received shall be properly acknowledged.
For inquiries and submission of proposals, please email us at
actamedicaphilippina.upm@up.edu.ph**