

# Ruptured Community-acquired Methicillin-Resistant *Staphylococcus aureus* (MRSA) Hepatic Abscess in an Immunocompetent Child Treated Successfully with Culture-guided Antibiotic Therapy: A Case Report

Jeremiah C. Torrico, RND, MD<sup>1</sup> and Paul Sherwin O. Tarnate, MD<sup>2</sup>

<sup>1</sup>Department of Nutrition, College of Public Health, University of the Philippines Manila

<sup>2</sup>Division of Infectious and Tropical Diseases in Pediatrics, Department of Pediatrics - College of Medicine, Philippine General Hospital, University of the Philippines Manila

## ABSTRACT

Methicillin-resistant *Staphylococcus aureus* (MRSA) is an uncommon etiologic agent of hepatic abscess in children, particularly those without an underlying immunocompromised condition.

We describe a rare case of community-acquired MRSA (CA-MRSA) hepatic abscess with rupture into the anterior abdominal wall in an otherwise healthy 3-year-old Filipino male, manifesting as a one-week history of an enlarging epigastric mass accompanied by abdominal pain and fever. He was treated noninvasively with ciprofloxacin (intravenous at 10 mg/kg every 12 hours for 14 days followed by oral at 15 mg/kg every 12 hours for 28 days), and clindamycin (intravenous at 10 mg/kg every 6 hours for 14 days followed by oral at 10 mg/kg every 6 hours for 28 days), resulting in the resolution of the hepatic abscess and its associated symptoms.

CA-MRSA hepatic abscess is extremely rare in immunocompetent children, and an appropriate diagnostic approach involving imaging and culture studies is crucial in its diagnosis and management.

**Keywords:** Methicillin-Resistant *Staphylococcus aureus*, MRSA, liver abscess, hepatic abscess, community-acquired, tuberculosis

## INTRODUCTION

Hepatic abscess continues to pose a significant health burden, particularly among children in developing countries, where it remains a significant cause of morbidity. This condition arises from the accumulation of encapsulated suppurative material within the liver parenchyma, resulting from the invasion and proliferation of pathogenic microorganisms. While the etiology of hepatic abscesses is diverse, methicillin-resistant *Staphylococcus aureus* (MRSA), in particular, is a rare pathogen in this context, especially in the absence of underlying immunocompromised or predisposing factors.

We present a rare case of a community-acquired MRSA (CA-MRSA) hepatic abscess in an otherwise healthy 3-year-old Filipino male. This report underscores the need for heightened clinical awareness and consideration of atypical pathogens in pediatric hepatic abscess, even in immunocompetent individuals.

Poster presentation – 10<sup>th</sup> Congress of the European Academy of Paediatric Societies (EAPS 2024), October 17-20, 2024, Austria Center Vienna, Vienna, Austria.

Corresponding author: Jeremiah C. Torrico, RND, MD  
Department of Nutrition  
College of Public Health  
University of the Philippines Manila  
Pedro Gil Street, Ermita, Manila 1000, Philippines  
Email: jctorrico@up.edu.ph  
ORCID: <https://orcid.org/0000-0002-4353-2504>

## CASE PRESENTATION

A 3-year-old Filipino male presented with a one-week history of an enlarging abdominal mass in the epigastric region, accompanied by intermittent low-grade fever and uncharacterized abdominal pain. The review of systems was unremarkable, with no history of recurrent infections or notable events in his past medical and ancillary pediatric history.

On examination, the child appeared awake, ambulatory, and not in acute distress, exhibiting normal nutritional status per anthropometric measurements. The abdomen was non-distended but notable for an erythematous, fluctuant, tender mass in the epigastric region. The mass was inseparable from the liver and was associated with direct and rebound tenderness. There were also noted multiple hyperpigmented patches and macules on the lower extremities.

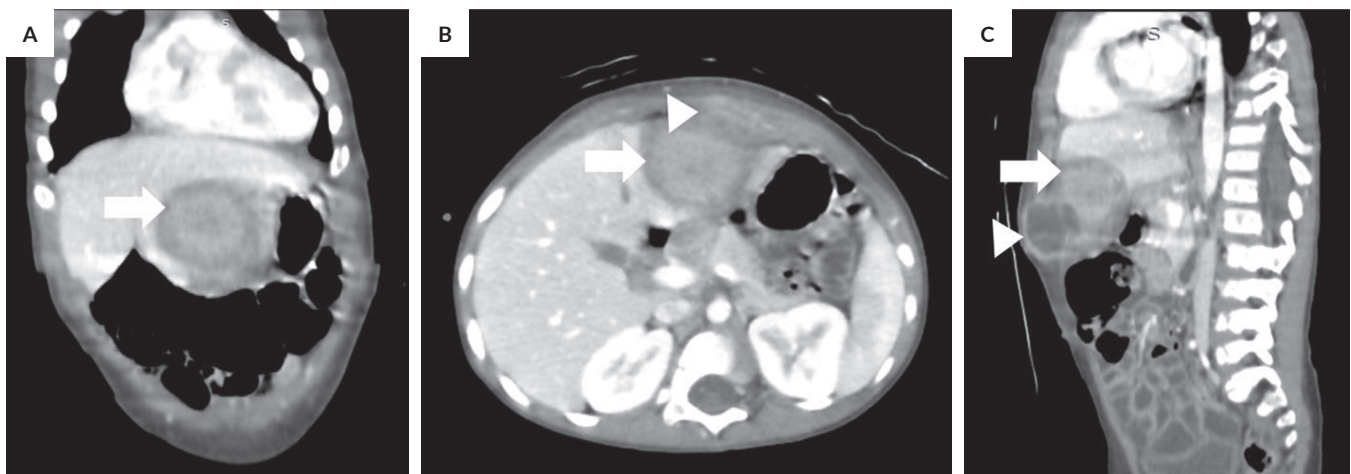
### Investigations

On diagnostic work-up, the patient had anemia with hemoglobin of 87 g/dL (N: 11.5-15.5 g/dL) and hematocrit of 28% (N: 34-40%), leukocytosis with neutrophilic predominance (WBC  $26.5 \times 10^3/\mu\text{L}$ , N:  $5.5\text{-}15.5 \times 10^3/\mu\text{L}$ ; neutrophils 67%, N: 23-45%), and thrombocytosis at  $778 \times 10^3/\mu\text{L}$  (N:  $150\text{-}450 \times 10^3/\mu\text{L}$ ). Liver function was preserved with normal prothrombin time, bilirubin, and serum albumin, together with normal liver enzymes. Inflammatory markers C-reactive protein (CRP) and procalcitonin were elevated at 96 mg/mL (N: <1mg/mL) and 0.62 ng/mL (N: <0.05 ng/mL), respectively. Blood culture as well as tuberculosis work-up, including sputum Acid Fast Bacilli (AFB) smear, GeneXpert® (Cepheid, USA), and bacterial culture, all yielded negative results. Stool studies such as direct fecal smear, stool antigen tests, and stool culture were likewise unremarkable.

Hepatobiliary ultrasound revealed two focal lesions in the liver: (1) an ill- to fairly well-defined, heterogeneous, predominantly hypoechoic mass in segment II-III ( $\sim 3.6 \times 3.1 \times 1.9$  cm) with small anechoic foci interspersed within, exhibiting extracapsular component with the anterior aspect abutting the abdominal wall; and (2) an ill- to fairly well-defined, heterogeneous, predominantly hyperechoic mass in segment IVa ( $\sim 2.7 \times 3.2 \times 3.1$  cm).

Further imaging with contrast-enhanced abdominal computed tomography (CT) scan revealed a fairly defined, heterogeneously enhancing focus at the left liver lobe (segment II/III) measuring approximately  $4.3 \times 4.1 \times 3.4$  cm, with associated perilesional edema (Figure 1). The mass compresses some peripheral radicles of the left intrahepatic ducts posteriorly, resulting in segmental dilatation. Additionally, a peripherally enhancing fluid collection with internal septation was identified at the anterior abdominal wall, measuring  $3.5 \times 2.4 \times 3.2$  cm, with an approximate volume of 14 mL. This collection abutted the left liver lobe posteriorly and was surrounded by fat stranding. These findings were consistent with a hepatic abscess that had ruptured into the anterior abdominal wall.

Ultrasound-guided aspiration of the abscess yielded 5 mL of yellow-green purulent aspirate, and random core needle biopsy of the liver yielded 8 cores of liver tissue of 1 cm each. Culture of the hepatic abscess aspirate showed growth of MRSA resistant to Oxacillin and Penicillin G, but sensitive to Ciprofloxacin, Clindamycin, Vancomycin, Linezolid, and others. The full MIC-based susceptibility profile is summarized in Table 1. Histopathology of the liver tissue showed non-neoplastic liver tissue with mild periportal chronic inflammation with negative acid-fast bacilli stain.



**Figure 1.** Abdominal CT scan with contrast revealed a fairly defined heterogeneous enhancing focus in liver segments II/III, approximately  $4.3 \times 4.1 \times 3.4$  cm (A, B, and C, arrows). There was a peripherally enhancing fluid collection at the anterior abdominal wall measuring  $3.5 \times 2.4 \times 3.2$  cm with an approximate volume of 14 mL (B and C, arrowheads). (A) Coronal view; (B) Axial view; (C) Sagittal view.

**Table 1.** Antimicrobial Susceptibility Profile of MRSA Isolate from Hepatic Abscess (CLSI 2024 criteria)

Antibiotic	MIC (µg/mL)	Interpretation
Ciprofloxacin	<0.5	Susceptible
Cotrimoxazole	<1	Susceptible
Gentamicin	<0.5	Susceptible
Tetracycline	<1	Susceptible
Linezolid	2	Susceptible
Clindamycin	<0.25	Susceptible
Erythromycin	<0.25	Susceptible
Levofloxacin	0.25	Susceptible
Vancomycin	1	Susceptible
Moxifloxacin	<0.25	Susceptible
Oxacillin	>2	Resistant
Penicillin G	>0.25	Resistant

Note: Antibiotic susceptibility testing was performed using the VITEK 2 Compact system (bioMérieux, France), and MIC interpretations followed Clinical and Laboratory Standards Institute (CLSI) M100, 32<sup>nd</sup> Edition (2022).

## Differential Diagnoses

Most pyogenic liver abscesses are polymicrobial, accounting for ~80% of liver abscesses.<sup>1</sup> Mixed enteric and anaerobic species are the most common pathogens, as high as 1 in every 3 cases.<sup>2</sup> The highly variable microbiology justifies pursuing a microbiological diagnosis in virtually every case. Enteric gram-negative bacilli are generally the most commonly identified pathogens, with *Escherichia coli* and *Klebsiella pneumoniae* being the most common agents.<sup>3</sup> In Asian developed countries, *K. pneumoniae* is an important cause of primary liver abscess, while streptococcal and staphylococcal species, particularly methicillin-sensitive *S. aureus* (MSSA), were the most common pathogens in other Asian populations.<sup>4</sup>

*Entamoeba histolytica*, together with *S. aureus*, is more prevalent in developing countries. Amoebic abscesses account for ~10% of liver abscesses, with the liver being the most common extra-intestinal site of amoebic infections, but occur in less than 1% of *E. histolytica* infections.<sup>5</sup> Anaerobes are probably under-reported because they are difficult to culture and characterize in the laboratory, and sensitive markers for amoebic infection, like indirect hemagglutination assay or enzyme immunoassay, are not commonly used.

Tuberculous liver abscesses (TLA) are common in developing countries in Asia and are reported in endemic areas such as the Philippines, where the incidence of tuberculosis remains high.<sup>6</sup> However, isolated TLA without active pulmonary or miliary tuberculosis or other clinical evidence of tuberculosis is distinctly rare.

## Treatment

The patient initially received empiric intravenous ceftriaxone (50 mg/kg every 12 hours) and metronidazole (10

mg/kg every 8 hours) for 7 days prior to abscess aspiration. Following the release of aspirate culture and susceptibility results, the antibiotic regimen was shifted to a combination of ciprofloxacin (intravenous at 10 mg/kg every 12 hours for 14 days followed by oral at 15 mg/kg every 12 hours for 28 days), and clindamycin (intravenous at 10 mg/kg every 6 hours for 14 days followed by oral at 10 mg/kg every 6 hours for 28 days), as guided by the culture results and by pediatric infectious diseases experts. All antibiotics were tolerated with no note of any adverse events. The patient was admitted for a duration of three weeks to facilitate the diagnostics and management with intravenous antibiotics. Adjunctive measures included the daily chlorhexidine digluconate 4% body washes and the application of topical mupirocin ointment to the nostrils for decolonization over the course of one week.

## Outcome and Follow-up

Upon completion of treatment, there was resolution of the mass and its associated fever and abdominal pain. There were no noted adverse events during treatment, and the patient was able to resume all activities of daily living independently. Repeat abdominal CT scan at one week after initiation of culture-guided antibiotic treatment showed resolution of the previously noted fairly-defined, heterogeneously-enhancing focus seen in the left liver lobe, particularly in segments II and III, as well as the previously noted peripherally enhancing fluid.

## DISCUSSION

Hepatic abscesses are encapsulated collections of suppurative material formed within otherwise healthy or diseased liver parenchyma due to the invasion and proliferation of microorganisms. Although uncommon, they remain a notable infectious issue in children, particularly in areas where healthcare resources are limited, such as in developing countries.<sup>7</sup> Pyogenic hepatic abscess in children is a rare clinical condition with associated significant morbidity, especially in children in developing countries, with *S. aureus* responsible for less than 10% of hepatic abscesses, and fewer are caused by MRSA. Epidemiological studies reveal varying prevalence rates of liver abscesses worldwide. In North America, the incidence is 2.3 per 100,000, compared to 275.4 in Taiwan.<sup>8</sup> In the Philippines, studies have shown that hepatic abscesses in pediatric patients are often linked to *S. aureus*, with MRSA accounting for a notable proportion of cases. For instance, a 2018 study at the Philippine Children's Medical Center, a tertiary pediatric specialty hospital, reported MRSA in 40% of patients with positive hepatic abscess cultures.<sup>9</sup> Similarly, data from the Philippine General Hospital (PGH), a tertiary referral hospital, revealed MRSA as the isolate in 6% of pediatric liver abscess cases, although most of these patients have immunocompromised conditions such as malnutrition.<sup>10</sup>

In the sole case report of CA-MRSA hepatic abscess in an immunocompetent child, a 6-year-old boy presented with right lower abdominal pain and fever.<sup>11</sup> Physical examination revealed a soft abdomen with no palpable masses. Laboratory findings showed leukocytosis, elevated CRP, and an increased erythrocyte sedimentation rate (ESR), while liver function tests and other parameters remained within normal limits, findings similar to those observed in our reported case. Imaging via CT scan demonstrated multiple heterogeneous hepatic lesions consistent with abscesses, and magnetic resonance imaging (MRI) identified soft tissue inflammation around the left hip joint, indicating a soft tissue abscess around the left femur, which complicated the management. The patient experienced persistent febrile episodes until the soft tissue abscess was incised and drained, leading to the resolution of fever. Except for the soft tissue abscess, this case closely resembles our patient's clinical presentation and course. In the previously reported case, the soft tissue abscess likely served as the source of MRSA, whereas in our case, no identifiable direct source of infection was found except for the scars on the lower extremities, which could have been the source of previous MRSA infection, possibly eventually reaching the systemic circulation before lodging in the liver to form the abscess.

CA-MRSA possesses various virulence factors, including Pantón-Valentine leukocidin (PVL), which contributes to severe infections such as skin and soft tissue infections. PVL activates cytochrome c, triggering caspase-9 and caspase-3 activation, leading to DNA fragmentation and apoptosis.<sup>12</sup> PVL-mediated epithelial necrosis and cytolysis in polymorphonuclear cells (PMNs) occurs at high PVL loads, resulting in tissue necrosis and further inflammation through macrophage recruitment. Conversely, low PVL loads induce apoptosis in PMNs, minimizing inflammation. In abscess formation, *S. aureus* recruits PMNs and triggers phagocytosis, causing edema and signaling of resident Langerhans cells within 2 to 24 hours. Within 2 to 6 days, inflammation leads to the development of a fibrous capsule, and by days 6 to 14, phagocytosis of entrapped bacteria results in liquefactive and coagulative necrosis. This progression culminates in abscess formation as necrotic or lysed PMNs accumulate.

Pediatric liver abscesses present with a range of non-specific symptoms, such as abdominal pain and fever.<sup>13</sup> Yeh et al. identified fever in 94.7% of cases, followed by right upper quadrant abdominal pain (42.1%), pleural effusion (34.2%), vomiting (23.7%), and diarrhea (18.4%).<sup>14</sup> In the Philippines, fever is the most prevalent symptom (84%), along with abdominal pain (72%) and distension (52%).<sup>15</sup> Diarrhea (40%), weight loss (36%), chest pain, and edema were observed less frequently. Common clinical signs included high fever ( $\geq 39^\circ\text{C}$ , 84%), right upper quadrant tenderness (76%), hepatomegaly (72%), and palpable masses (48%). Anemia, jaundice, and splenomegaly were also noted. Another local study in the Philippines emphasized abdominal distension (32%) and weight loss (30%) as prominent symptoms, along-

side vomiting, anorexia, and abdominal pain.<sup>10</sup> Fever was universal (100%), and key clinical signs included palpable abdominal masses (30%), right upper quadrant tenderness (22%), jaundice (15%), hepatomegaly (10%), and ascites (13%). Overall, these studies highlight fever and abdominal symptoms as consistent features of pediatric liver abscesses, with variations in prevalence reflecting differences in populations and methodologies.

Management of pediatric liver abscesses should be culture-guided to ensure targeted antimicrobial therapy. The duration of antimicrobial therapy for pyogenic liver abscess generally spans 4 to 6 weeks, depending on clinical response and adequacy of drainage. Intravenous therapy is usually initiated and may transition to oral antibiotics once the patient shows signs of improvement. Imaging follow-up helps determine the total duration. Shorter durations may be appropriate if the abscess is well-drained and the patient responds rapidly to therapy.<sup>16</sup> Prolonged treatment is considered in cases of incomplete source control, large abscesses, or immunocompromised status. Empiric antibiotic regimens for liver abscesses often include broad-spectrum coverage, combining agents such as ciprofloxacin and clindamycin to ensure both aerobic and anaerobic organisms are targeted. This combination is synergistic: ciprofloxacin provides robust coverage against gram-negative bacilli, while clindamycin enhances anaerobic coverage. The importance of anaerobic coverage cannot be overstated, as anaerobes are frequently implicated but difficult to isolate from culture.<sup>14</sup> Tailoring the regimen based on culture results and sensitivity is ideal, but not always possible. Beyond pharmacologic management, source control via percutaneous or surgical drainage is pivotal. Successful drainage leads to reduced abscess volume, facilitates antibiotic penetration, and accelerates clinical improvement. Lack of adequate source control is associated with persistent infection and higher complication rates. Percutaneous catheter drainage has become the preferred initial intervention due to its minimally invasive nature and high success rate, but surgical drainage remains an important alternative in complex or multiloculated abscesses.<sup>17</sup> In the Philippines, the preferred regimen for hepatic abscess includes antibiotics with coverage for Gram-negative and anaerobic microorganisms, such as ampicillin-sulbactam or a combination of a third-generation cephalosporin (e.g., ceftriaxone) and metronidazole.<sup>18</sup> Infections caused by MRSA are generally treated with clindamycin or vancomycin.

The decision to drain a liver abscess depends on its size and the patient's clinical response to antibiotics. For abscesses greater than 5 cm in diameter, percutaneous aspiration with intracavitary catheter placement is recommended. If this intervention fails, a repeat aspiration should be performed, followed by surgical drainage (either open or laparoscopic) if necessary. Smaller abscesses may be managed initially with antibiotic therapy alone, with percutaneous aspiration reserved for cases that fail to respond to medical management. Percutaneous needle aspiration (PNA) may be an option in

smaller abscesses within the liver when specific criteria are met, such as rim thickness >1 cm and very low-level ultrasonographic echoes suggesting liquefaction.<sup>19</sup> This stepwise approach to management, integrating appropriate antibiotic therapy and drainage techniques, optimizes outcomes while minimizing complications in pediatric liver abscess cases.

The availability of timely imaging, prompt initiation of antibiotics, and percutaneous drainage when indicated has remarkably improved survival over the past three decades, with modern management reducing mortality to less than 15%.

## CONCLUSION

Hepatic abscesses are rare findings in children, with CA-MRSA being an uncommon etiologic agent. Despite its rarity, MRSA hepatic abscesses should always be considered as a differential diagnosis in pediatric patients presenting with liver abscesses, even in the absence of an immunocompromised state. This highlights the need for heightened clinical suspicion, especially in regions where *S. aureus* is a prevalent pathogen.

An appropriate diagnostic approach is crucial for the accurate diagnosis and effective management of liver abscesses in children. Imaging modalities such as ultrasonography and computed tomography (CT) play a pivotal role in identifying the presence and characteristics of abscesses. Additionally, obtaining culture studies, whenever feasible, is essential for confirming the causative organism and guiding targeted antimicrobial therapy.

Management of hepatic abscesses extends beyond antimicrobial treatment. Close monitoring during therapy, prevention of recurrence, and addressing potential risk factors are integral components of comprehensive care. A multidisciplinary approach, including infectious disease consultation and management of comorbid conditions, optimizes outcomes and reduces the risk of complications in pediatric patients with hepatic abscesses.

## Ethics Approval and Consent to Participate

This case report was registered in the Research Grants Administration Office of the University of the Philippines Manila and was exempted from full panel ethics review. Written consent was obtained from the legal guardian of the patient for the documentation and processing of this case.

## Consent for Publication

Written consent was secured from the father of the patient for the publication of this case and the images included for documentation.

## Statement of Authorship

Both authors certified fulfillment of ICMJE authorship criteria.

## Author Disclosure

Both authors declared no conflicts of interest.

## Funding Support

This study was funded by the Department of Pediatrics of the PGH for a poster presentation at the 10<sup>th</sup> Congress of the European Academy of Paediatric Societies (EAPS 2024).

## REFERENCES

1. Heneghan HM, Healy NA, Martin ST, Ryan RS, Boland MR, Winter DC. Modern management of pyogenic hepatic abscess: a case series and review of the literature. *BMC Res Notes*. 2011 Mar;4:80. doi:10.1186/1756-0500-4-80. PMID: 21435221; PMCID: PMC3073909.
2. Johannsen EC, Sifri CD, Madoff LC. Pyogenic liver abscesses. *Infect Dis Clin North Am*. 2000 Sep;14(3):547-63, vii. doi: 10.1016/s0891-5520(05)70120-3. PMID: 10987109.
3. Wang H, Xue X. Clinical manifestations, diagnosis, treatment, and outcome of pyogenic liver abscess: a retrospective study. *J Int Med Res*. 2023 Jun;51(6):3000605231180053. doi: 10.1177/03000605231180053. PMID: 37345580; PMCID: PMC10291412.
4. Qu TT, Zhou JC, Jiang Y, Chang Y, Wang Y, Chen Y, et al. Clinical and microbiological characteristics of *Klebsiella pneumoniae* liver abscess in East China. *BMC Infect Dis*. 2015 Mar;15:161. doi: 10.1186/s12879-015-0899-7. PMID: 25886859; PMCID: PMC4381403.
5. Haque R, Mollah NU, Ali IK, Alam K, Eubanks A, Lysterly D, et al. Diagnosis of amebic liver abscess and intestinal infection with the TechLab Entamoeba histolytica II antigen detection and antibody tests. *J Clin Microbiol*. 2000 Sep;38(9):3235-9. PMID: 10970364; PMCID: PMC87365.
6. Capul EP, Gregorio GEV, Gonzales MLAM. Features and outcome of hepatobiliary tuberculosis among Filipino children: report of a six-year experience. *Acta Med Philipp*. 2020 Oct;54(5):551-7. doi: 10.47895/amp.v54i5.2251.
7. Muorah M, Hinds R, Verma A, Yu D, Samyn M, Mieli-Vergani G, et al. Liver abscesses in children: a single center experience in the developed world. *J Pediatr Gastroenterol Nutr*. 2006 Feb;42(2):201-6. doi: 10.1097/01.mpg.0000189344.98524.1b. PMID: 16456416.
8. Mavilia MG, Molina M, Wu GY. The evolving nature of hepatic abscess: a review. *J Clin Transl Hepatol*. 2016 Jun;4(2):158-68. doi: 10.14218/JCTH.2016.00004. PMID: 27350946; PMCID: PMC4913073.
9. Lu AM, Nolasco ME, Tan M. Clinical profile and factors affecting outcome of Filipino children with hepatic abscess: 19 year study. *PIDSP Journal*. 2018 Jul-Dec;19(2):17-28.
10. Besa LM, Gregorio GEV. Pediatric hepatic abscess: a ten-year review of the features and outcome at the Philippine General Hospital. *Acta Med Philipp*. 2022 May;56(9):46-52. doi: 10.47895/amp.v56i9.3607.
11. Wu X, Ye YZ, Wang CQ, Wang AM, He LY, Yu H. A case report of hepatic abscesses with soft tissue infection caused by methicillin resistant *Staphylococcus aureus* in a young child. *Medicine (Baltimore)*. 2017 Dec;96(50):e9331. doi: 10.1097/MD.00000000000009331. PMID: 29390368; PMCID: PMC5815780.
12. Boyle-Vavra S, Daum RS. Community-acquired methicillin-resistant *Staphylococcus aureus*: the role of Panton-Valentine leukocidin. *Lab Invest*. 2007 Jan;87(1):3-9. doi: 10.1038/labinvest.3700501. PMID: 17146447; PMCID: 17146447.
13. Lardi.re-Deguelte S, Ragot E, Amroun K, Piardi T, Dokmak S, Bruno O, et al. Hepatic abscess: diagnosis and management. *J Visc Surg*. 2015 Sep;152(4):231-43. doi: 10.1016/j.jvisurg.2015.05.005. PMID: 25770745.

14. Yeh PJ, Chen CC, Lai MW, Yeh HY, Chao HC. Pediatric liver abscess: trends in the incidence, etiology, and outcomes based on 20 years of experience at a tertiary center. *Front Pediatr*. 2020 Mar;8:559270. doi: 10.3389/fped.2020.559270. PMID: 32266189; PMCID: PMC7105830.
15. Tejam-Baclayon M, Bravo L, Gabriel E, Sio J, Rogacion J, Avila J. Liver abscess in children: a review of cases at Philippine General Hospital [Internet]. 1996 [cited 2022 Apr 20]. Available from: [http://www.pidsphil.org/home/wp-content/uploads/2017/02/jo14\\_ja03.pdf](http://www.pidsphil.org/home/wp-content/uploads/2017/02/jo14_ja03.pdf).
16. Johns Hopkins ABX Guide. Hepatic Abscess [Internet]. [cited 2025 May 13]. Available from [https://www.hopkinsguides.com/hopkins/view/Johns\\_Hopkins\\_ABX\\_Guide/540259/all/Hepatic\\_Abscess](https://www.hopkinsguides.com/hopkins/view/Johns_Hopkins_ABX_Guide/540259/all/Hepatic_Abscess).
17. Kaplan GG, Gregson DB, Laupland KB. Population-based study of the epidemiology of and the risk factors for pyogenic liver abscess. *Clin Gastroenterol Hepatol*. 2004 Nov;2(11):1032–8. doi: 10.1016/S1542-3565(04)00417-6. PMID: 15551257.
18. Department of Health (Philippines). National Antibiotic Guidelines 2017 [Internet]. Manila: Department of Health; 2017 [cited 2022 Apr 20]. Available from: <http://thepafp.org/website/wp-content/uploads/2017/05/2017-National-Antibiotic-Guidelines-DOH.pdf>.
19. Srivastava A, Yachha SK, Arora V, Poddar U, Lal R, Baijal SS. Identification of high-risk group and therapeutic options in children with liver abscess. *Eur J Pediatr*. 2012 Jan;171(1):33–41. doi: 10.1007/s00431-011-1470-4. PMID: 21537924.