

Management of Asymptomatic Irreversible Pulpitis with Single-visit Endodontic Treatment and Minimally Invasive Indirect Restoration: A Case Report

Irfan Fauzy Yamin and Noor Hikmah

Department of Conservative Dentistry, Faculty of Dentistry, Hasanuddin University, Makassar, Indonesia

ABSTRACT

Patient's need for endodontic treatment in a short period is on the rise nowadays. Technological developments in instruments and materials are allowing single-visit endodontic treatment to be performed. The success of an endodontic treatment is also influenced by the restoration, in consideration of the remaining tooth structure. This becomes a challenge for the clinician if the cavities are large or if minimal tooth structure remains, so it needs a minimally invasive restoration like morphology-driven preparation technique. This case report aims to describe the single-visit endodontic treatment and minimally invasive indirect restoration of the mandibular first molar.

A 13-year-old girl came to the Dental Hospital of Hasanuddin University with complaints of cavities in the mandibular left posterior tooth and pain for one month. The patient had taken analgesic medication but was afforded no relief. Intraoral examination showed tooth #36 with extensive cavities reaching the proximal area, a positive thermal test, and no pain to percussion. The case diagnosis was asymptomatic irreversible pulpitis. The treatment plan was a single-visit endodontic treatment and minimally invasive indirect restoration.

Keywords: *asymptomatic irreversible pulpitis, single-visit endodontic treatment, root canal treatment, minimally invasive restoration, onlay restoration, case report*

INTRODUCTION

The endodontic treatment is a dental procedure to prevent and stop further pulp and periradicular pathology to preserve the tooth.¹ Endodontic treatment can be performed either in multiple visits or single visit.² Multiple-visit endodontic treatment involves a minimum procedure of three visits, resulting in a longer treatment time. Developments in dental technology, such as Ni-Ti rotary files, apex locators, ultrasonics, magnification equipment, digital radiography, and biocompatible sealing materials, make it easier for clinicians to perform endodontic procedures more effectively and efficiently. Therefore, endodontic treatment can be completed in a single visit.^{3,4}

Single-visit endodontic treatment is a non-surgical endodontic treatment that involves root canal preparation, disinfection, and obturation in a single visit. The indications for single-visit endodontic treatment include uncomplicated vital teeth, non-vital teeth with sinus tracts, aesthetic needs in tooth fracture with pulp involvement, patients with physical limitations, and intentional endodontic treatment. The contraindications to single-visit endodontic treatment include non-vital teeth with acute inflammation, teeth with



eISSN 2094-9278 (Online)
Published: January 15, 2026
<https://doi.org/10.47895/amp.vi0.10093>
Copyright: The Author(s) 2026

Corresponding author: Noor Hikmah
Department of Conservative Dentistry
Faculty of Dentistry
Hasanuddin University
Makassar, Indonesia
Email: noorhikmah@unhas.ac.id
ORCID: <https://orcid.org/0000-0002-3881-6991>

anatomical anomalies, and limited mouth opening access due to TMJ disorders.⁴⁻⁷

The success of endodontic treatment is supported by endodontic post-treatment restorations because adequate coronal sealing can increase the success of endodontic treatment by up to 90%.⁸ Onlay indirect restorations with a minimally invasive approach are an option as post-endodontic treatment restorations with extensive tooth structure damage.⁹ The development of advances in material science, adhesion system mechanisms, and good isolation techniques make indirect restorations with a minimally invasive approach based on adhesion systems that can be achieved effectively. This is challenging and involves biomechanical, aesthetic, and economic considerations.¹⁰ The treatment in this case is a single-visit endodontic treatment and minimally invasive indirect restoration, which provides a faster workflow with good results and is an appropriate treatment option for patients with limited time. The uniqueness of this case is that it provides shorter endodontic treatment and minimally invasive restoration with a more conservative preparation technique, morphology-driven preparation technique. The patient does not have to wait long to get a good result, compared to a multiple-visits endodontic case treatment. Single-visit endodontic treatment needs to match the indication of the case. In addition, tooth restoration with morphology-driven preparation (minimally invasive indirect restoration) provides an adequate restoration by relying on the adhesive system of the restoration without taking more tooth structure. The purpose of this case report is to describe the management of asymptomatic irreversible pulpitis of the mandibular first molar with single-visit endodontic treatment and minimally invasive indirect restoration.

CASE PRESENTATION

A 13-year-old girl came to the Dental Hospital of Hasanuddin University with complaints of cavities and pain since a month ago. The patient had taken analgesic medication but was still in pain. The patient had not been treated

previously. The patient is not experiencing pain at present. The patient has no history of systemic disease. Intraoral examination showed tooth #36 with extensive cavities reaching the proximal area, a positive cold thermal test, and no pain to percussion. A periapical radiograph showed normal periapical and straight roots (Figure 1). On examination, the case diagnosis was asymptomatic irreversible pulpitis. The treatment plan was a single-visit endodontic treatment and an onlay indirect restoration. The treatment plan was given with medical consideration of the diagnosis and the absence of complicating factors in the tooth, and the patient requested that treatment be done as soon as possible. The prognosis of this case was good considering the indication of single-visit endodontic treatment with an onlay indirect restoration. Informed consent and treatment alternatives such as multi-visit endodontics were given. The patient agreed to single-visit endodontic treatment with minimally invasive indirect restoration. The patient gave informed consent for the treatment procedure and documentation, including clinical photos and digital radiographic images in this case.

Single-visit endodontic treatment began with local anesthesia and rubber dam placement. Carious tissue removal and cavity rewalling were performed, and then pulp access was opened with an endo access bur (Dentsply, Switzerland). Root canal exploration and the establishment of the working length with an electronic apex locator (Propex Pixi, Dentsply Sirona, Switzerland) were confirmed by radiograph (Figure 2).

Root canal preparation began with glide path preparation using a ProGlider (Dentsply Maillefer, Switzerland). The single-length root canal preparation technique using Protaper Next (Dentsply Maillefer, Switzerland) until file number #X2. Irrigation using 5.25% NaOCl (Chloraxid, CerKamed, Poland), aquadest, 17% EDTA (Indodent EDTA, Onemed, Indonesia) at each file change, then activation using an ultrasonic device (Ultra-X, Eighteenth, China).

Trial gutta-percha using gutta-percha #X2 (Dentsply Maillefer, Switzerland) was done and was confirmed by radiograph (Figure 3). The single cone obturation technique used gutta-percha and resin-based sealer (Adseal, Meta

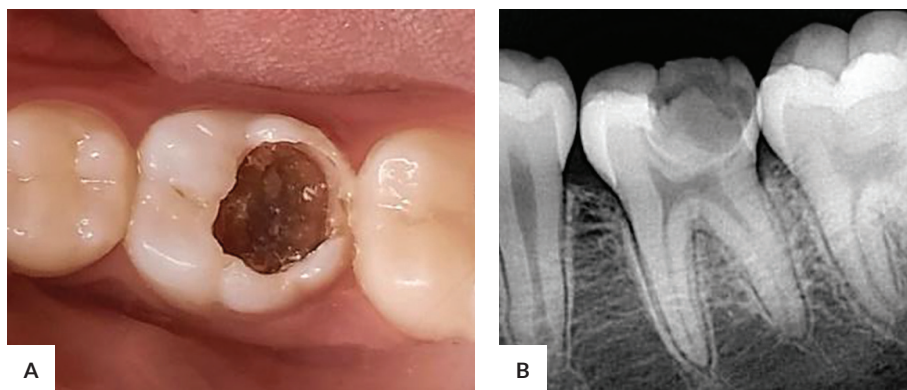


Figure 1. Initial (A) clinical and (B) periapical radiograph.

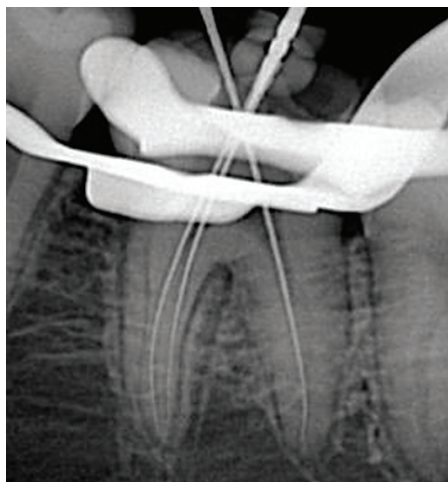


Figure 2. Establishing the working length.

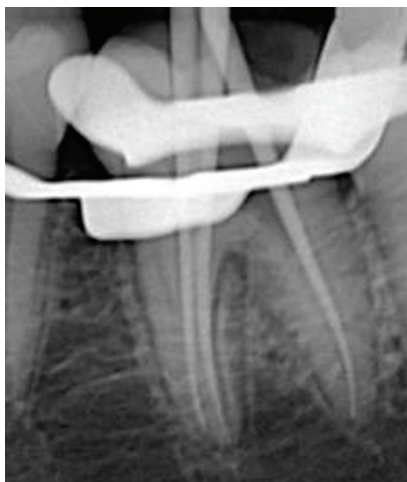

Figure 3. Trial gutta-percha.

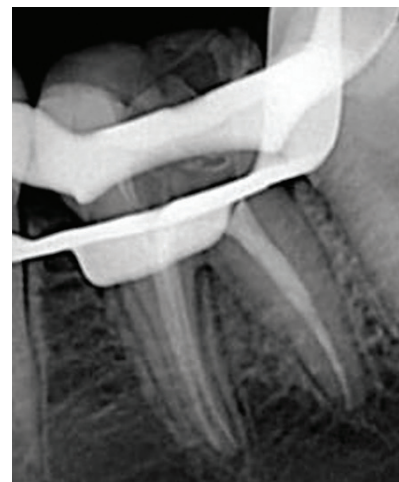

Figure 4. Root canal obturation.

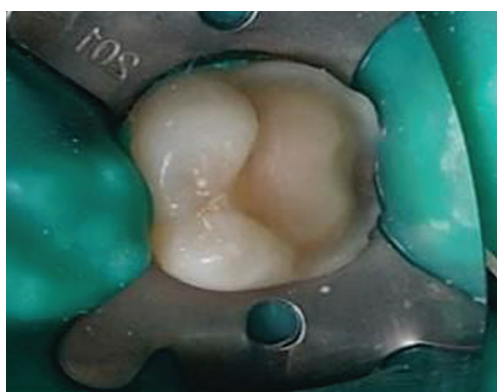

Figure 5. Tooth preparation design.

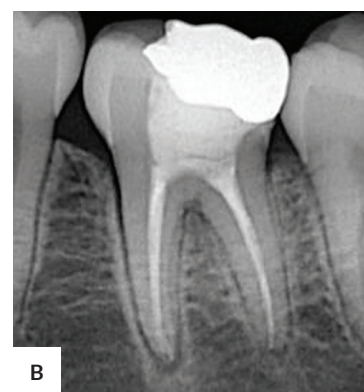
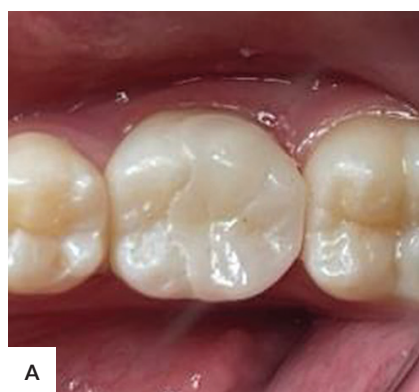

Figure 6. Post-treatment (A) clinical and (B) periapical radiograph.

Biomed, South Korea) and was confirmed by radiograph (Figure 4). Next, RMGIC material was placed as a base, and an interim restoration was placed (Cavition, GC, Japan).

On the second visit (three days later), a control was performed and there were no complaints from the patient after single-visit endodontic treatment and no pain on percussion test. Cavity preparation was performed for indirect onlay restorations using a minimally invasive approach. The preparation technique used was a morphology-driven preparation technique. The remaining tooth structure on the mesiobuccal and mesiolingual cusps was preserved. The core build-up was performed on the distobuccal and distolingual cusps, and then a cusp reduction preparation was performed with a depth of 1.5 mm and maintained the morphological shape of the mandibular first molar (Figure 5).¹¹ An impression was taken using the double impression technique with elastomer impression material, and laboratory instructions were conducted. The interim restoration was placed (Light-Cured Temporary Resin, Ezy Crown, Medicus, Korea).

On the third visit (seven days later), zirconia onlay indirect restorations were inserted using a resin cement adhesive system (Figure 6). Occlusion and marginal integrity

checks were performed. Upon follow-up after seven days, the patient had no complaints, the restoration was still good, no premature contact, no pain to bite test, and the patient considered the treatment results satisfactory.

DISCUSSION

Single-visit endodontic treatment can reduce treatment time and costs, minimize the risk of bacterial contamination, and prevent pain between visits. In this case, single-visit endodontic treatment was performed on an asymptomatic irreversible pulpitis case. The vital teeth have a low incidence of pain because bacterial invasion has not yet reached the root canal. In this case, the tooth showed mature roots and straight root canals, and the patient was still young, making it easier to perform single-visit endodontic treatment. Mergoni showed there is currently no evidence to suggest that single-visit or multiple-visit endodontics treatment are more effective than the other. There was moderate certainty evidence of a higher proportion of patients reporting pain within one week in single-visit endodontic treatment compared to multiple-visit endodontic treatment. In this case, the patient

did not experience any complaints of pain after a single-visit endodontic treatment.¹²⁻¹⁴

The success of single-visit endodontic treatment depends on root canal preparation, disinfection, and root canal obturation. The endodontic preparation technique used a single-length preparation technique with a NiTi Protaper Next rotary instrument (Dentsply Maillefer, Switzerland) because it has higher flexibility, strength, and fatigue resistance, can be used in root canals with small diameters, and a more efficient file sequence that provides optimal root canal shape results and good root canal cleanliness in a short time.¹⁵⁻¹⁷

Root canal disinfection using a 5.25% NaOCl solution that acts as an antimicrobial and dissolves organic tissue works effectively and efficiently in single-visit endodontic treatment cases. Another irrigation material is an EDTA solution to remove the smear layer and release the attached biofilm. Root canal irrigation is performed with ultrasonic passive activation, which aims to remove debris and smear layers more effectively in the root canal. Studies have shown that teeth with root canal irrigation activation have cleaner root canals than those without.¹⁸⁻²⁰

In the root canal obturation, a single cone technique is used with the gutta-percha conforming to the last file with a sealer adapted to the root canal wall. The advantage of this technique is that it does not require gutta-percha accessories and shortens the root canal obturation time.²¹

Mandibular first molar with extensive cavity damage, such as missing the marginal ridge and part of the cusp, has a risk of fracture due to heavy masticatory load, so a zirconia onlay indirect restoration was performed in this case. The zirconia material was considered because it has flexural strength and higher compressive strength, which makes it withstand masticatory load and has good aesthetic properties. In this case, the preparation principle uses a minimally invasive approach, so removing a lot of tooth structure is unnecessary. The morphology-driven preparation technique improves durability by preserving the remaining tooth structure, increasing bond strength and marginal integrity with the remaining tooth structure, and improving the restoration's aesthetics. With these properties, zirconia onlay indirect restorations with a minimally invasive approach provide adequate coronal sealing and good fracture resistance, increasing the success rate of single-visit endodontic treatment.^{10,22-24} Single-visit endodontic treatment with minimally invasive indirect restoration provides shorter treatment time and satisfactory results for the patient. The disadvantage of the treatment is the need for proper case selection and patient cooperation to receive treatment because the endodontic treatment will take 2-3 hours. The limitation of this case report is that no further follow-up was carried out to assess the durability of the restoration.

CONCLUSION

The management of asymptomatic irreversible pulpitis with single-visit endodontic treatment and indirect restoration with a minimally invasive approach in the mandibular first molar provides the advantage of shortening endodontic treatment. Minimally invasive indirect restoration provided satisfactory results with no patient complaints after treatment evaluation. Single-visit endodontic treatment and minimally invasive indirect restoration can be performed according to the case indication and consideration of the remaining tooth structure.

Acknowledgments

The authors would like to thank all the staff of the Department of Conservative Dentistry, Faculty of Dentistry, Hasanuddin University, Makassar, Indonesia and the Dental Hospital of Hasanuddin University, Makassar, Indonesia.

Statement of Authorship

All authors certified fulfillment of ICMJE authorship criteria.

Author Disclosure

All authors declared no conflicts of interest.

Funding Source

None.

REFERENCES

1. Karia H, Pujari P, Bhardwaj M, Detroja K, Karia M, Takkar H. A study to assess perception of dentist regarding single-visit root canal treatment at dental clinics in India. *J Pharm Negat Results*. 2022 Nov;13(9):821-824. doi: 10.47750/pnr.2022.13.S09.096
2. Manfredi M, Figini L, Gagliani M, Lodi G. Single versus multiple visits for endodontic treatment of permanent teeth. *Cochrane Database Syst Rev*. 2016 Dec;12(12): 1-5. doi: 10.1002/14651858.CD005296. pub3. PMID: 27905673. PMCID: PMC6463951
3. Wong AW, Tsang CS, Zhang S, Li KY, Zhang C, Chu CH. Treatment outcomes of single-visit versus multiple-visit non-surgical endodontic therapy: a randomised clinical trial. *BMC Oral Health*. 2015 Dec;15(1):1-1. doi: 10.1186/s12903-015-0148-x. PMID: 26687126. PMCID: PMC4684923
4. Kaur, G., Gupta, A., Bansal, C. Single visit endodontics with associated myths: A review. *Int J Health Sci*. 2021 Jul; 5(S1):143-8. doi: 10.53730/ijhs.v5nS1.5408
5. Ariani MK, Zubaidah N. Successful single visit endodontic using bioceramic sealer and esthetic restoration with porcelain fused to zirconia: a case report. *Health Notions*. 2022 Jun; 6(6):287-91. doi: 10.33846/hn60607
6. Abdelmawgoud A, Fawzy MI, Elhousiny MA, Abdel-Aziz MM. Evaluation of single visit endodontic treatment outcome in teeth with asymptomatic necrotic pulp and apical periodontitis using endovac irrigation device: randomized controlled clinical trial. *Al-Azhar Dent J Girls*. 2022 Jul; 9(3): 431-9. doi: 10.21608/ADJG.2022.136422.1500
7. Mohammadi Z. How can single-visit root canal treatment be optimized? *Int. J. Clin. Dent*. 2022 Jan;15(1): 1-5

8. Atlas A, Grandini S, Martignoni M. Evidence-based treatment planning for the restoration of endodontically treated single teeth: importance of coronal seal, post vs no post, and indirect vs direct restoration. *Quintessence Int.* 2019 Nov; 50(10): 772-81. doi: 10.3290/j.qi.a43235. PMID:31559397
9. Xiao W, Chen C, Yang T, Zhu Z. Influence of different marginal forms on endodontically treated posterior teeth restored with lithium disilicate glass-ceramic onlays: two-year follow-up. *Int J Prosthodont.* 2020 Jan;33(1):22-8. doi: 10.11607/ijp.6356. PMID: 31860910
10. Hegde VR, Joshi SR, Hattarki SA, Jain A. Morphology-driven preparation technique for posterior indirect bonded restorations. *J Conserv Dent.* 2021 Jan;24(1):100-4. doi: 10.4103/JCD.JCD_489_20. PMID: 3447568. PMCID: PMC8378497
11. Veneziani M. Posterior indirect adhesive restorations: updated indications and the Morphology Driven Preparation Technique. *Int J Esthet Dent.* 2017 Jun;12(2):204-30. PMID: 28653051
12. Jacob S. Single visit endodontics. In: Jacob S. *Famdent Practical Dentistry Handbook*. San Francisco: Scribd Inc. 2006 Jun. pp 1-6.
13. Dennis C, Nurliza, C. Single visit endodontic in the management of symptomatic irreversible pulpitis and pulp necrosis with apical periodontitis: report of two cases. *Int J Dentistry Oral Sci.* 2017 Feb; 4(2): 418-421.
14. Mergoni G, Ganim M, Lodi G, Figini L, Gagliani M, Manfredi M. Single versus multiple visits for endodontic treatment of permanent teeth. *Cochrane Database of Systematic Reviews.* 2022 Dec; 12(12). doi: 10.1002/14651858.CD005296.pub4. PMID: 36512807. PMCID: PMC9747194
15. Patil AA, Joshi SB, Bhagwat SV, Patil SA. Incidence of postoperative pain after single visit and two visit root canal therapy: a randomized controlled trial. *J Clin Diagn Res.* 2016 May; 10(5): 9-12. doi: 10.7860/JCDR/2016/16465.7724. PMID: 27437339. PMCID: PMC4948515
16. The shaping advantage of M-wire compared with conventional nickel-titanium rotary instruments in heavy curvature canal: summary research finding [Internet]. 2020 Aug [cited 2023 Dec]. Available from: <http://www.researchsquare.com/article/rs-47617/v1>
17. Gallottini L. Shaping of the root canal system: a multistep technique. *J Contemp Dent Pract.* 2017 Sep; 18(9): 851-855. doi: 10.5005/jp-journals-10024-2138. PMID: 28874653
18. Maity I, Meena N, Kumari A. Single visit nonsurgical endodontic therapy for periapical cysts: a clinical study. *Contemp Clin Dent.* 2014 Apr; 5: 195. doi: 10.4103/0976-237X.132321. PMID: 24963246. PMCID: PMC4067783
19. Rudranaik S, Nayak M, Babshet M. Periapical healing outcome following single visit endodontic treatment in patients with type 2 diabetes mellitus. *J Clin Exp Dent.* 2016 Dec; 8(5): e498-504. doi: 10.4317/jced.52859. PMID: 27957260. PMCID: PMC5149081
20. Vivan RR, Duque JA, Alcalde MP, Reis So MV, Bramante CM, Duarte MAH. Evaluation of different passive ultrasonic irrigation protocols on the removal of dentinal debris from artificial grooves. *Brazilian Dental Journal.* 2016 Sep; 27(5): 568-572. doi: 10.1590/0103-6440201600725. PMID: 27982235
21. Pereira AC, Nishiyama CK, Pinto LC. Single cone obturation technique: a literature review. *RSBO.* 2012 Jun. 9(4):442- 447.
22. Liu MC. Restoration of endodontically treated premolars and molars: a review of rationales and techniques. *J Prosthodont Implant.* 2014 Aug; 3(1): 2-16. doi: 10.6926/JPI.201408_3(1).0001
23. Polesel A. Restoration of the endodontically treated posterior tooth. *G Ital Endod.* 2014 Jun; 28(1):2-16. doi: 10.1016/j.gien.2014.05.007
24. Sakaguchi R, Ferracane J, Powers J. *Craig's Restorative Dental.* 14th ed. Missouri: Elsevier; 2016 Dec. p.213

**Have you read the current trends in
Medical and Health Research in the Philippines?**

Acta Medica Philippina

The National Health Science Journal

Access Online: www.actamedicaphilippina.upm.edu.ph